

Case Study**METASTATIC RENAL CELL CARCINOMA PRESENTING AS GASTRIC POLYPS****ABSTRACT:**

Metastatic tumors of the stomach are very rare, with an incidence of 0,2%- 0,7% in the autopsy series. Malignant melanoma, carcinomas of breast, esophagus and lung are the most frequent primary tumor sites. The present case describes a A 57-year-old woman that presented to the gastroenterology department with epigastric pain, nausea and vomiting for two months. Examinations revealed gastric metastasis of Renal Cell Carcinoma.

Keywords: Renal Cell Carcinoma; Metastasis; Stomach

Case Presentation

A 57-year-old woman was admitted to the hospital complaining of epigastric pain, nausea and vomiting for two months. The patient had a history of right radical nephrectomy for renal cell carcinoma (RCC) seven years ago. She continued on hemodialysis three times per week because of her atrophic left kidney. The upper endoscopy revealed multiple polypoid masses (2 to 4 cm in diameter) with ulcerations at the corpus of the stomach. Microscopic examination of the biopsies revealed nodular and nested collections of epithelioid clear cells invading lamina propria. Tumor cells showed clear cytoplasm, round to ovoid nuclei with finely granular open chromatin and small, inconspicuous nucleoli. Tumor cells were immunoreactive with antibodies raised against Vimentin and PANCK. The histomorphologic features and the immunophenotype resulted in a diagnosis of metastatic RCC (Figures 1 and 2). Abdominal and thoracic computed tomography scan revealed multiple metastatic lesions on both lungs.

Metastatic tumors of the stomach are rare, with an incidence of 0,2%-0,7% in the autopsy series. Malignant melanoma, carcinomas of breast, esophagus and lung are the most frequent primary tumor sites (1).

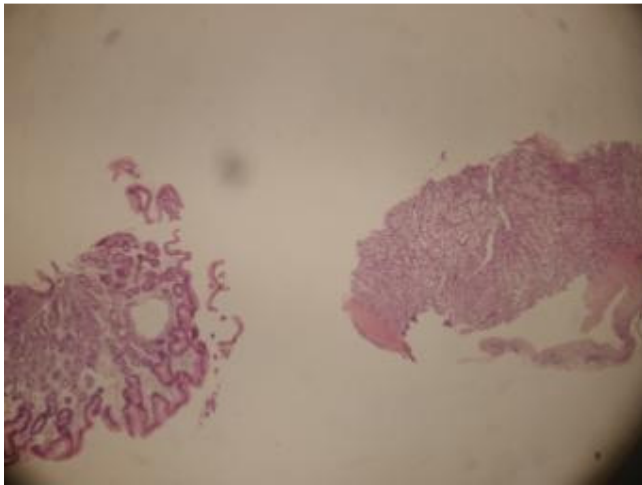
RCC frequently metastasizes to distant organs such as lungs, bones, brain, liver and lymph nodes. However, gastric metastasis from RCC is extremely rare with only 44 cases in the literature reviewed by Herculano et al (2). Gastric metastasis from RCC may be a slow process. The mean period from diagnosis of RCC to diagnosis of metastasis is nearly 7 years

(0-23 years) (3). Our patient also had a history of nephrectomy seven years ago. The most common symptoms and signs include gastrointestinal bleeding (melena or hematemesis), epigastric pain, anemia from occult blood loss, nausea and vomiting. Our patient presented with epigastric pain, nausea and vomiting. Gastric metastasis from RCC may present as polypoid (a large solitary mass or multiple small polyps) or ulcerated lesions (4). It usually tends to be a single polypoid lesion. In our case, multiple, polypoid masses in the gastric body were noted (Figure 3).

Gastric metastasis is usually associated with advanced disease due to concomitant presence of metastases in other organs. Several therapeutic approaches for gastric metastasis from RCC can be considered however since the survival period is extremely short the optimal treatment remains controversial. Total or subtotal gastrectomy, surgical or endoscopic polypectomy, chemotherapy with systemic or targeted drugs are available (5, 6). Our patient refused any further treatment procedure and the palliative treatment was performed. The patient died 2 months after the gastric endoscopy.

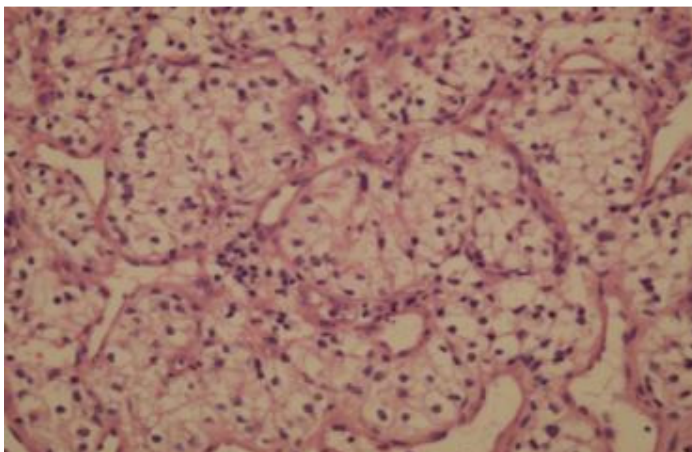
REFERENCES

1. Namikawa T, Hanazaki K. Clinicopathological features and treatment outcomes of metastatic tumors in the stomach. *Surg Today*. 2014; 44(8): 1392-9.
2. Harculano R, Alves I. Treatment of gastric metastases from renal cell carcinoma with endoscopic therapy. *Clin J Gastroenterol* 2014 Vol: 7(2):1-7.
3. Sakurai K, Muguruma K, Yamazoe S, et al. Gastric metastasis from renal cell carcinoma with gastrointestinal bleeding: a case report and review of the literature. *Int Surg*. 2014;99(1): 86-90.
4. Xu J, Latif S, Wei S. Metastatic renal cell carcinoma presenting as gastric polyps: A case report and review of the literature. *Int J Surg Case Rep* 2012; 3(12): 601-4.
5. Namikawa T, Munekage M, Kitagawa H, Okabayashi T, Kobayashi M, Hanazaki K. Metastatic gastric tumors arising from renal cell carcinoma: Clinical characteristics and outcomes of this uncommon disease. *Oncol Lett*. 2012;4(4): 631-636.
6. Gómez-de-la-Cuesta S, Fernández-Salazar L, Velayos-Jiménez B, Macho-Conesa A. Gastric metastasis from renal cell carcinoma *Rev Esp Enferm Dig*. 2012; 104(6): 334-5.

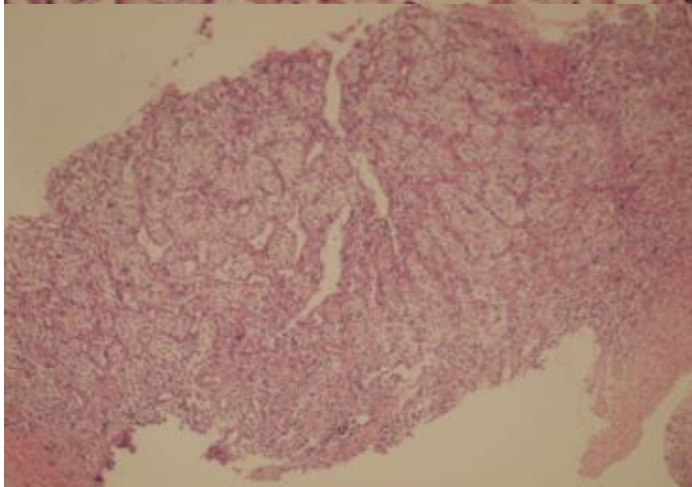


65

66 Figure 1: Biopsies from normal gastric mucosa and metastatic mucosa (H&E, 10X)



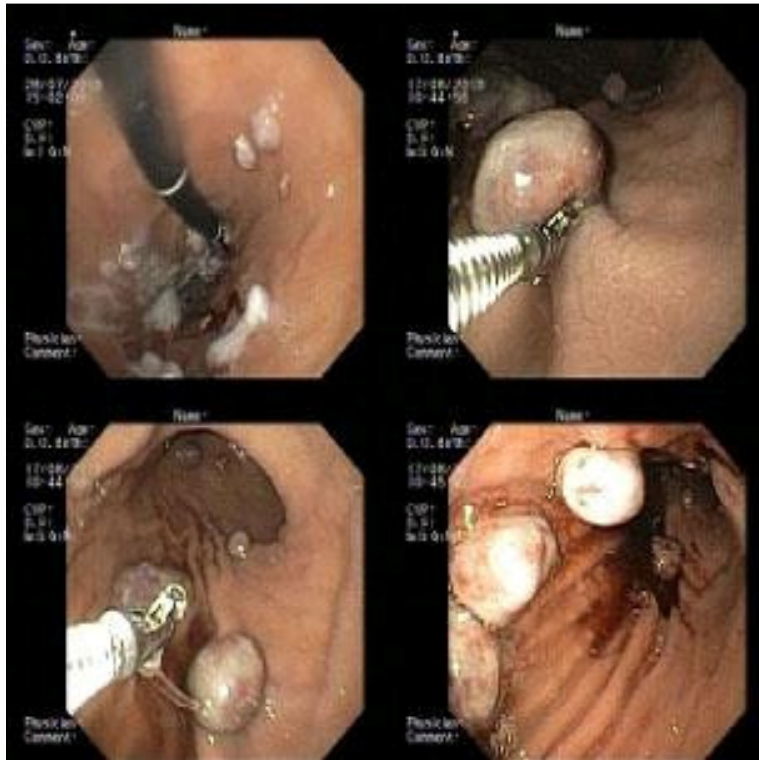67



68

69 Figure 2: Submucosal nodular collections of epithelioid clear cells, typical histologic
70 characteristics of RCC in gastric mucosa (H&E, original magnification 40X and 100X).

71



72

73

74 Figure 3: Multiple, polypoid masses in the corpus of stomach.

75