

Original Research Article

Thymectomy in children with juvenile myasthenia gravis: Is it recommended?

Abstract:

Objective:

Juvenile myasthenia gravis (JMG) is a rare disease with possible severe forms. Thymectomy is supported by many authors particularly in generalised forms with positive AcetylCholine Receptor Antibody (AChR- Ab). The aim of our study was to discuss the indication and the outcome of thymectomy in five children with JMG.

Methods:

We performed a retrospective study of the medical files of patients with JMG, who were hospitalised in our pediatric surgery department for thymectomy. For all the children we performed Acetylcholine Receptor Autoantibody (ACHRAB) test-system producer , a chest x-ray, a chest Computed Tomography Scan (CT-scan) and a Magnetic Resonance Imaging (MRI).

Thymectomy was indicated on the presence of anomalies on CT-Scan or MRI and realised via either thoracotomy or video-assisted thoracoscopy.

The study was conducted with the approval of the ethics committee at our institution.

Results:

Based on our findings, thymectomy in JMG with imaging anomalies seems to be associated with clinical improvement. In our patients complete remission after surgery was seen in one case, a clinical improvement with a decrease of the medical therapeutic dosage was noted in

three other cases. One patient could not be evaluated because of non adherence to medical treatment.

Surgery by thoracotomy or video assisted thoracoscopy (VAT) was also well tolerated by all the patients.

Conclusion:

The benefits of thymectomy in children with JMG is still controversial. However, many researchers have reported a sustained improvement of symptoms in the majority of patients after thymectomy. Our findings seem to encourage thymectomy in cases of JMG and particularly when imaging anomalies are found. VAT thymectomy was well tolerated and it is considered by many researchers to be the standard method for thymectomy in children.

Keywords: Juvenile myasthenia gravis, thymectomy, children, thoracoscopy.

Abbreviations and acronyms:

JMG: juvenile myasthenia gravis

AChR-Ab: acetylcholine receptor autoantibody

CT-Scan: computed tomography scan

MRI: magnetic resonance imaging

VAT: video assisted thoracoscopy

OMG: ocular myasthenia gravis

43 **Introduction:**

44 Juvenile myasthenia gravis (JMG) is a rare auto-immune disorder of neuromuscular
45 transmission caused by the production of antibodies against components of postsynaptic
46 membrane of the neuro-muscular junction (1). Young patients may present severe forms with
47 generalised muscle weakness with or without respiratory insufficiency. Specific treatment is
48 needed including immunosuppressive therapy and thymectomy particularly in presence of
49 thymus abnormalities (1-3). The aim of our study is to discuss indication and outcome of
50 thymectomy in children with JMG.

51 **Patients and Methods:**

52 We performed a retrospective study of the medical files of patients with JMG hospitalised in
53 our pediatric surgery department for thymectomy.

54 Diagnosis of JMG was established in pediatric departments based on a combination of clinical
55 symptoms and positive pyridostigmine test. Disease severity was evaluated according to
56 Osserman Classification. For all patients, we performed Acetylcholine Receptor Autoantibody
57 (ACHRAB) test-system producer, a chest x-ray, a chest Computed Tomography Scan (CT-
58 scan) and a Magnetic Resonance Imaging (MRI).

59 All patients received a medical treatment which consisted of pyridostigmine and
60 corticotherapy.

61 Thymectomy was indicated in case of thymic anomalies on CT-Scan or MRI. It was realized
62 either via thoracotomy or with video-assisted thoracoscopy (VAT). VAT was introduced in
63 our department in 2009.

64

65 **Results:**

66 Five patients (table1) were included, 1 male and 4 females with sex ratio of 0.25. Mean age
67 was 7.7 years (2.5 to 14 years old). Four patients had a generalised JMG and one had an
68 ocular myasthenia gravis (OMG). Only one patient was AChR-Ab positive. Prior to
69 thymectomy, disease severity was graded as I for one patient, IIa for two patients and IIb for
70 two other patients.

71 Mediastinal enlargement was noticed on the chest x-ray of two patients (Fig1). The CT-scan
72 showed the presence of an eventual thymoma in three cases(Fig2) and a thymus hypertrophy
73 in the two other cases.

74 An **extended** thymectomy (Fig3) was indicated for all the patients. It was realised via antero-
75 lateral thoracotomy in three cases and via VAT in two cases.

76 The initial post operative course was complicated by a pneumothorax in case 2, related to a
77 pleural breach, successfully managed by assisted mechanical ventilation and pleural drainage.

78 Microscopic examination found a follicular hyperplasia in four cases (Fig4-5) and was normal
79 for the remaining case.

80 Four patients experienced a clinical improvement within the **first year after thymectomy**. A
81 complete remission and **a tolerated medical wean** occurred **two years after thymectomy** in
82 case1 which was AchR-Ab positive.

83 A clinical improvement with medical treatment decrease was obtained in the three other
84 patients. **Unfortunately** one patient **could not** be evaluated because of non adherence to
85 medical treatment.

86 Clinical improvement started within the first year after surgery with medical wean during the
87 second year for case 1 and medical decrease for the

88

89

90

91 **Discussion:**

92 Management of JMG was initially adopted from adult patients, whereas recent studies have
93 showed that JMG is different in presentation and in the course of the disease, particularly the
94 group of prepubertal children (3-5).

95 Actually, children with JMG exhibit higher rates of remission than adults. This includes
96 spontaneous remission and remission following a period of drug therapy. Prepubertal children
97 have the highest rates of spontaneous remission (2, 6).

98 Therapeutic strategies for JMG have been established. Medical treatment as first line therapy
99 consists of pyridostigmine associated to steroids and long term immunosuppression in
100 generalised muscular weakness and moderate to severe bulbar symptoms or respiration
101 insufficiency. Plasmapheresis can be indicated in severe forms (1).

102 All of our patients received pyridostigmine, associated to steroids in two cases and steroids
103 with immunosuppression in one case.

104 Because of the presumed role of the thymus in the pathogenesis of myasthenia gravis,
105 thymectomy is a recognised aspect of management(2, 7).

Although, the fact of existing of immunological side effects after thymectomy during early childhood is still to be discussed (1), many researchers have argued against the surgical intervention in prepubertal patients (8).

We compared our findings with other series of thymectomised JMG (table2).

More patients with thymic hyperplasia achieved remission compared to patients with normal thymus (2). In our series, four patients had thymic hyperplasia, one of them showed a complete remission after surgery.

In JMG thymic hyperplasia is evident in 83% of patients and in 3.8% thymoma could be detected (1, 9).

Although the outcome of thymectomy has not been evaluated with randomised controlled trials in children, some case series have suggested that remission rate following thymectomy in JMG is higher than the remission rate with or without medical treatment (3, 10;11).

Thymectomy is followed by improvement in most cases: remission rate was higher in children after thymectomy than in the group of spontaneous evolution (1, 7, 9, 11-13).

Chao Cheng et al made a comparison of major series of patients with JMG who underwent thymectomy from different areas of the world with his own study (135 patients). He noted a comparable complete remission rate after surgery across the different series, which varied between 37.5 - 60% (11).

Thymectomy is recommended as early as possible in case of generalised weakness (1).

The duration between disease onset and thymectomy is a significant predictor of the efficacy after surgery in generalised JMG. Remission is higher if thymectomy is performed within the first year after onset (1, 6, 11, 13, 15, 16).

More recent review of children, including prepubertal patients, also suggested increased remission rates after thymectomy (2, 13, 15, 17).

Chao Cheng et al suggested an algorithm for treatment of juvenile myasthenia gravis (JMG) patients based on age (>12 years old), Osserman classification (>I), duration of the disease (≥ 24 months) and medical treatment response (11).

Current evidence suggests that thymectomy should not be indicated in Musk-positive disease as it is unclear whether it confers any benefit (3, 18-20). In our patients Musk-antibodies were not practiced.

Thymectomy in pure OMG remains controversial. Whereas OMG is not life threatening, patients may be dependent on long term immunosuppressant medications, including corticosteroids with the resultant side effects which can be substantial in children. Thymectomy has been performed in refractory cases (2).

A variety of surgical methods for thymectomy have been described: full or partial sternotomy, thoroscopic or transcervical approaches (2, 21-22).

Many authors recommend a transsternal approach in children to prevent incomplete removal of all thymic tissue, which may lead to poor outcome (3, 23).

Less invasive techniques such as VAT thymectomy are now resulting in comparable remission rates following thymectomy in adult MG (3, 24).

Della Marina et al recommend thoroscopic techniques but these are restricted to specialised centers (1).

Kolski HK et al (25) has applied VAT to a group of juvenile patients for thymectomy and compared it to a similar group of six patients (in terms of age and clinical severity) operated

150 via a median transsternal approach. He concluded that VAT thymectomies are comparably
151 effective to transsternal procedures in treating generalised JMG and can be safely performed
152 in children as young as 20 months of age. In addition, VAT surgery is less invasive and
153 significantly shortens the postoperative hospital stay, and has superior cosmetic results.

154 In our series, thymectomy was performed via antero-lateral thoracotomy in three cases.
155 Thoracotomy was practiced by our surgical team because they mastered it better than
156 sternotomy. VAT was introduced recently and served to treat the two other cases.

157 A larger series with a randomised controlled study is necessary to elucidate the benefit of
158 thymectomy in JMG and to compare results of different surgical methods.

159 **Conclusion:**

160 The benefit of thymectomy in children with JMG is still controversial. However, many
161 researchers have reported a sustained improvement of symptoms in the majority of patients
162 after thymectomy. Although the number of our patients is too few to indicate any treatment
163 recommendations, our findings seem to encourage thymectomy in case of JMG and
164 particularly when imaging anomalies are found. VAT thymectomy was well tolerated and it is
165 considered by many researchers to be the standard method for thymectomy in children.

166 Randomised controlled trials are necessary to elucidate the advantages of thymectomy and to
167 establish a clear treatment algorithm for children with JMG.

168

169

170

171

172

173

174

175 **References**

- 176 1. Della Marina A, Trippe H, Lutz S, Schara U. Juvenile Myasthenia Gravis:
 177 recommendations for diagnostic approaches and treatment. *Neuro ped.* 2014; 45:75-
 178 83.
- 179 2. Fennis F M, Jayawant S. Juvenile myasthenia gravis: a paediatric perspective.
 180 *Autoimmune dis.* 2011;2011: 404101.
- 181 3. Heng HS, Lim M, Absoud M, Austin C, Clarke D, Wraige E et al. Outcome of
 182 children with acetylcholine receptor (AChR) antibody positive juvenile myasthenia
 183 gravis following thymectomy. *Neuromuscul disord.* 2014; 24(1):25-30.
- 184 4. Herrmann DN, Carney PR, Wald JJ. Juvenile myasthenia gravis treatment with
 185 immune globulin and thymectomy. *Pediatr Neurol.* 1998; 18(1):63-6.
- 186 5. Ionita CM, Ascadi G. Management of juvenile myasthenia gravis. *Pediatr Neurol.*
 187 2013; 48(2): 95-104.
- 188 6. Adndrews PI, Massey JM, Howard FM Jr, Sanders DB. Race, sex and puberty
 189 influence onset, severity and outcome in juvenile myasthenia gravis. *Neurology.* 1994;
 190 44(7):1208-14.
- 191 7. Hayashi A, Shiono H, Ohta M, Ohta K, Okumura M, Sawa Y. Heterogeneity of
 192 immunopathological features of AchR/MuSK autoantibody-negative myasthenia
 193 gravis. *J Neuroimmunol.* 2007; 189(1-2):163-8.

- 194 8. Sauce D, Larsen M, Fasternackels S, Duperrir A, Keller M, Grubeck-Loebenstien B et
195 al. Evidence of premature immune aging in patients thymectomized during early
196 childhood. *J Clin Invest.* 2009; 119(10):3070-8.
- 197 9. Evoli A, Batocchi AP, Bartoccioni E, Lino MM, Minisci C, Tonali P. Juvenile
198 myasthenia gravis with prepubertal onset. *Neuromuscul Disord.* 1998; 8(8): 561-7.
- 199 10. Rodriguez M, Gomez MR, Howard FM Jr, Taylor WF. Myasthenia gravis in children:
200 long term follow-up. *Ann Neurol.* 1983; 13(5): 504-10.
- 201 11. Cheng C, Liu Z, Xu F, Deng Z, Feng H, Lei Y et al. Clinical outcome of juvenile
202 myasthenia gravis after extended transsternal thymectomy in a Chinese cohort. *Ann*
203 *Thorac Surg.* 2013; 95 (3):1035-41.
- 204 12. Ware TL, Ryan MM, Kornberg AJ. Autoimmune myasthenia gravis, immunotherapy
205 and thymectomy in children. *Neuromuscul Disord.* 2012; 22(2):118-21.
- 206 13. Tracy MM, McRae W, Millichap JG. Graded response to thymectomy in children with
207 myasthenia gravis. *J Child Neurol.* 2009; 24(4):454-9.
- 208 14. Adams C, Theodorescu D, Murphy EG, Shandling B. Thymectomy in juvenile
209 myasthenia gravis. *J Child Neurol.* 1990; 5(3):215-8.
- 210 15. Hennessey IA, Long AM, Hughes I, Humphrey G. Thymectomy for inducing
211 remission in juvenile myasthenia gravis. *Pediatr surg int.* 2011, 27:591-4.
- 212 16. Seybold ME. Thymectomy in childhood myasthenia gravis. *Ann N Y Acad Sci.* 1998;
213 841: 731-41.
- 214 17. Castro D, Derisavifard S, Anderson M, Greene M, Iannaccone S. Juvenile myasthenia
215 gravis: a twenty-year experience. *J Clin Neuromuscul Dis.* 2013; 14(3):95-102.
- 216 18. Skeie GO, Apostolski S, Evoli A, Gilhus NE, IIIa I, Harms L et al. Guidelines for
217 treatment of autoimmune neuromuscular transmission disorders. *Eur J Neurol.* 2010;
218 17(7):893-902.

- 219 19. Sanders DB, El Salem K, Massey M, McConville and Vincent A. Clinical aspects of
 220 Musk antibody positive seronegative MG. *Neurol.* 2003; 60(12):1978-80.
- 221 20. Evoli A, Tonali PA, Padua L, Monaco ML, Scuderi F, Batocchi AP et al. Clinical
 222 correlates with anti-Musk antibodies in generalised seronegative myasthenia gravis.
 223 *Brain.* 2003; 126 (Pt10): 2304-11.
- 224 21. Meyer DM, Herbert MA, Sonhani NC, Tavakolian P, Duncan A, Bruns M et al.
 225 Comparative clinical outcomes of thymectomy for myasthenia gravis performed by
 226 extended transsternal and minimally invasive approaches. *Ann Thorac Surg.* 2009;
 227 87(2):385-90.
- 228 22. Lin MW, Chang YL, Huang PM and Lee YC. Thymectomy for non thymomatous
 229 myasthenia gravis: a comparison of surgical methods and analysis of prognostic
 230 factors. *Eur J Cardiothorac Surg.* 2010; 37(1):7-12.
- 231 23. Essa M, El-Madany Y, Hajjar W, Hariri Z, Al Mulhim F, Salih M et al. Maximal
 232 thymectomy in children with myasthenia gravis. *Eur J Cardiothorac Surg.* 2003;
 233 24(2):187-9.
- 234 24. Zahid I, Shahid S, Routledge T, Scarcei M. Video-assisted thoracoscopic surgery or
 235 transsternal thymectomy in the treatment of myasthenia gravis?. *Interact Cardiovasc*
 236 *Thorac Surg.* 2011;12(1): 40-6.
- 237 25. Holski HK, Kim PC, Vajsa J. Video-assisted thoracoscopic thymectomy in juvenile
 238 myasthenia gravis. *J Child Neurol.* 2001; 16(8):569-73.
- 239 26. Lindner A, Schalke B, Toyka KV. Outcome in juvenile-onset myasthenia gravis: a
 240 retrospective study with long-term follow-up of 79 patients. *J Neurol.* 1997; 244: 515-
 241 20.
- 242 27. Lakhoo K, Fonseca JD, Rodda J, Davies MRQ. Thymectomy in black children with
 243 juvenile myasthenia gravis. *Pediatr Surg Int.* 1997; 12(2/3):113-5.

28. Kanzaki M, Obara T, Sasano S, Hikawa Y, Onuki T. Long-term clinical outcome after extended thymectomy combined post-operative high-dose steroid therapy for juvenile myasthenia gravis. *Ann Thorac Cardiovasc Surg.* 2008; 14(2): 119-22.

29. Heckmann JM, Hansen P, Van Toorn R, Lubbe E, Janse van Rensburg E, Wilmshurst JM. The characteristics of juvenile myasthenia gravis among South Africans. *S Afr Med J.* 2012; 102:532-6.

30. Ware TL, Ryan MM, Kornberg AJ. Autoimmune myasthenia gravis, immunotherapy and thymectomy in children. *Neuromuscul Disord.* 2012; 22(2):118-21.

Figure legends:

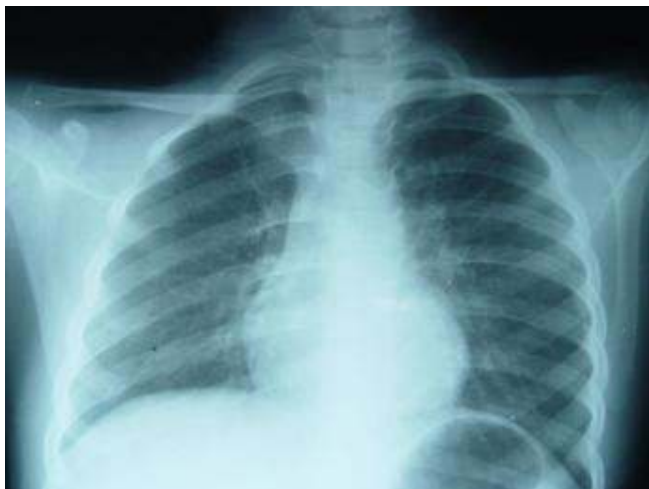Fig1: Chest x-ray: Mediastinal enlargement.

Fig2: Mediastinal CT-scan: shows the presence of a thymoma.

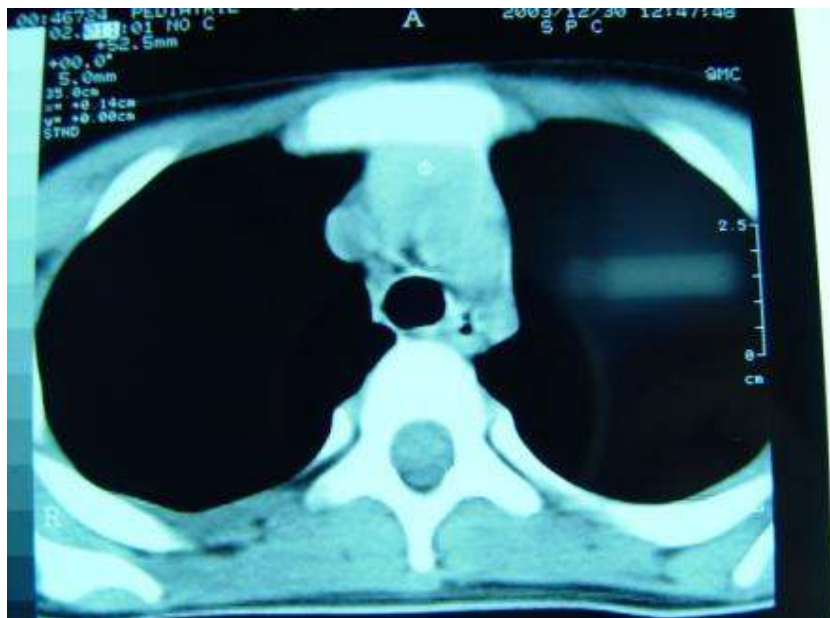Fig3: Complete thymectomy.

Fig4: Thymic hyperplasia (H&E, original magnification x200)

Fig5: Thymic hyperplasia (H&E, original magnification x400)

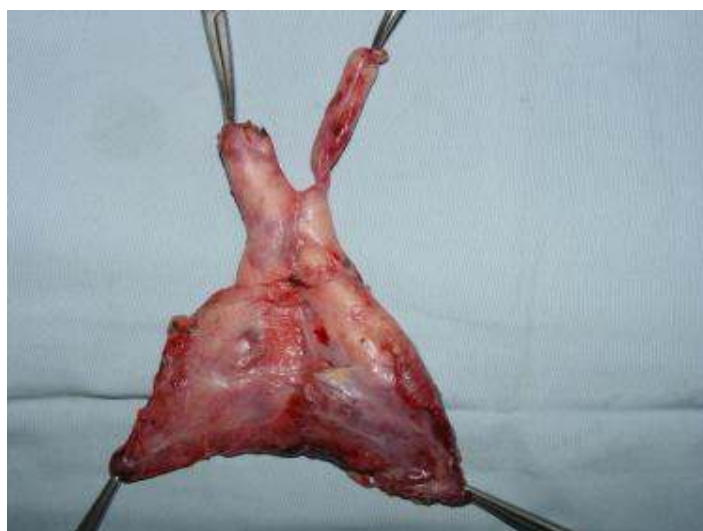


260 Fig1. Chest x-ray



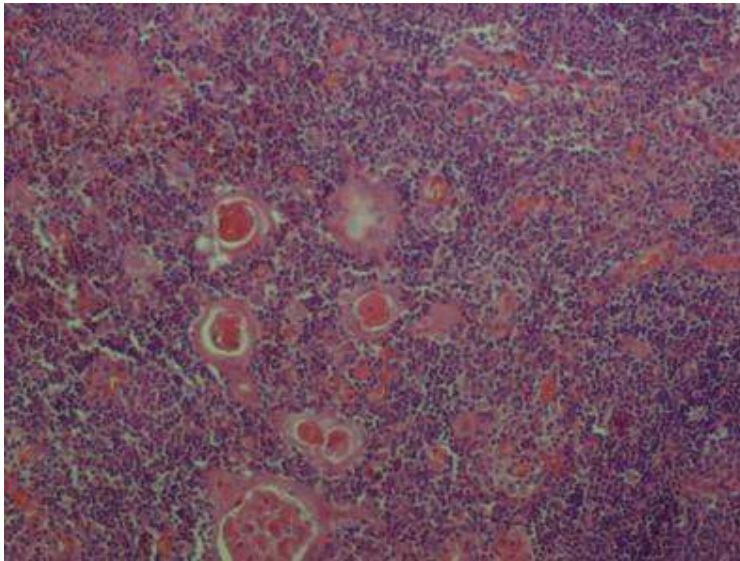
261

262 Fig2. Thoracic CT Scan



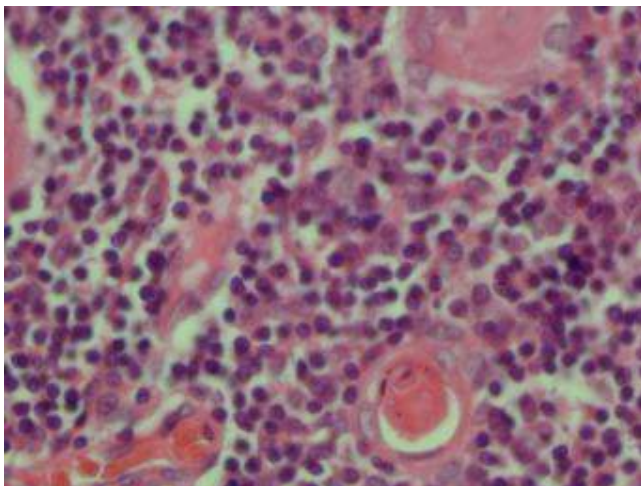
263

264 Fig3. Thymectomy



265

266 Fig.4 Histology. Thymic hyperplasia (H&E, original magnification x200)



267

268 Fig.5 Histology: Thymic hyperplasia (H&E, original magnification x400)

269

270

271

272

273

274

Table 1: data about the five patients with JMG

Case	Age (year)	Sex	Osseman classification	AchR-Ab	Imaging CT-Scan+/- MRI	Medical treatment Tablets/day	Surgery	Histology	Evolution/ Medical treatment Tablets/day
1	14	M	IIb	Positive	Thymoma	Pyridostigmine 6	Thoracotomy	Hyperplasia	Remission/No
2	2.5	F	Ia	Negative	Hypertrophy	Pyridostigmine 6	Thoracotomy	Hyperplasia	Improvement /yes 3
3	9	F	Ia	Negative	Thymoma	Pyridostigmine 3	Thoracotomy	Hyperplasia	Improvement/yes 2
4	10	F	IIb	Negative	Thymoma	Pyridostigmine 4	VAT	Normal	No improvement+ Non adherence to medical treatment
5	3	F	I	Negative	Hypertrophy	Pyridostigmine 3	VAT	Hyperplasia	Improvement/yes 2