

Case Study

GASTRIC METASTASIS OF RENAL CELL CARCINOMA PRESENTING AS POLYPS

ABSTRACT:

Metastatic tumors of the stomach are very rare, with an incidence of 0, 2%- 0, 7% in the autopsy series. Malignant melanoma, carcinomas of breast, esophagus and lung are the most frequent primary tumor sites. The present case describes a 57-year-old woman who presented to the gastroenterology department with epigastric pain, nausea and vomiting for two months. Examinations revealed gastric metastasis of Renal Cell Carcinoma.

Keywords: Renal Cell Carcinoma; Metastasis; Stomach; Upper Endoscopy; Kidney

26

27 INTRODUCTION

28 The presence of metastasis in the stomach is a rare condition with an incidence of 0, 2%-
29 0, 7% in the autopsy series. Most frequently described primary sites that lead to gastric
30 metastases include skin (malignant melanoma), breast, esophagus and lung (1). Renal Cell
31 Carcinomas originate within the renal cortex and constitute 80 to 85 percent of primary renal
32 neoplasms. Renal Cell Carcinoma can present with a range of sign and symptomsan at
33 presentation, approximately 25 percent of individuals either have distant metastases or
34 advanced locoregional disease (2).

35 CASE REPORT

36 A 57-year-old woman was admitted to the hospital complaining of epigastric pain,
37 nausea and vomiting for two months. The patient had a history of right radical nephrectomy
38 for renal cell carcinoma seven years ago. She continued on hemodialysis three times per week
39 because of her atrophic left kidney. The upper endoscopy revealed multiple polypoid masses
40 (2 to 4 cm in diameter) with ulcerations at the corpus of the stomach (Figure 1). Microscopic
41 examination of the biopsies revealed nodular and nested collections of epithelioid clear cells
42 invading lamina propria. Tumor cells showed clear cytoplasm, round to ovoid nuclei with
43 finely granular open chromatin and small, inconspicuous nucleoli. Tumor cells were
44 immunoreactive with antibodies raised against Vimentin and Pancytokeratin. The
45 histomorphologic features and the immunophenotype resulted in a diagnosis of metastatic
46 Renal Cell Carcinoma (Figures 2 and 3). Abdominal and thoracic computed tomography scan
47 revealed multiple metastatic lesions on both lungs. Our patient refused any further treatment
48 procedure and the palliative treatment was performed. The patient died 2 months after the
49 gastric endoscopy.

50 DISCUSSION

51 RCC frequently metastasizes to distant organs such as lungs, bones, brain, liver and
52 lymph nodes. However, gastric metastasis from RCC is extremely rare with only 44 cases in
53 the literature reviewed by Herculano et al (3). Gastric metastasis from RCC may be a slow
54 process. The mean period from diagnosis of RCC to diagnosis of metastasis is nearly 7 years
55 (0-23 years) an the majority of gastric metastases from RCCs occurred among male patients
56 (4). Our patient also had a history of nefrectomy seven years ago. An isolated gastric

metastasis from RCC was reported even 20 years after radical nephrectomy, suggesting RCC has the potential for late solitary metastasis (5). The most common symptoms and signs include gastrointestinal bleeding (melena or hematemesis), epigastric pain, anemia from occult blood loss, nausea and vomiting. Our patient presented with epigastric pain, nausea and vomiting. Gastric metastases are more common in the body (63%), and may presents as polypoid (a large solitary mass or multiple small polyps) or ulcerated lesions resembling primary gastric cancer endoscopically (6,7). The present patient had multiple, polypoid masses with various diameters in the gastric body (Figure 3).

Gastric metastasis is usually associated with advanced disease due to concomitant presence of metastases in other organs. The possibility for gastric metastasis even many years after diagnosis and treatment of RCC is crucial, particularly in patients with gastrointestinal symptoms. Several therapeutic approaches for gastric metastasis from RCC can be considered however since the survival period is extremely short the optimal treatment remains controversial. Total or subtotal gastrectomy, surgical or endoscopic polypectomy, chemotherapy with systemic or targeted drugs is available (8-10).

CONCLUSION

Gastric metastases of RCC are rare conditions with less than 50 cases described in the literature. Patients with RCC who undergo nephrectomy should be carefully followed up since early treatment of RCC metastases to distant organs play vital role for patient survival. These cases emphasize the need for careful long-term follow-up and endoscopy can have an important role in the diagnosis particularly in patients with gastrointestinal symptoms. However, the optimal treatment for RCC gastric metastasis remains unclear.

86

87

88

89

90

91

92 REFERENCES

93

94

95

96

97

98

99

100

101

102

103

104

105

106

107

108

109

110

111

112

113

114

115

116

117

1. Namikawa T, Hanazaki K. Clinicopathological features and treatment outcomes of metastatic tumors in the stomach. Surg Today. 2014; 44(8): 1392-9.

2. Campbell SC, Andrew CN. Renal tumours. In: Wein AJ, Kavoussi LR, Novick AC, et al., editors. Campbell-Walsh urology. 9th ed. Saunders Elsevier Pub; 2007. p. 1582–605.

3. Harculano R, Alves I. Treatment of gastric metastases from renal cell carcinoma with endoscopic therapy. Clin J Gasroenterol 2014 Vol: 7(2):1-7.

4. Sakurai K, Muguruma K, Yamazoe S, et al. Gastric metastasis from renal cell carcinoma with gastrointestinal bleeding: a case report and review of the literature. Int Surg. 2014;99(1): 86-90.

5. Kok Wee L., Shyu R.Y., Sheu L.F., Hsieh T.Y., Yan J.C., Chen P.J. Metastatic renal cell cancer. Gastrointestinal Endoscopy. 2004;60:265.

6. Xu J, Latif S, Wei S. Metastatic renal cell carcinoma presenting as gastric polyps: A case report and review of the literature. Int J Surg Case Rep 2012; 3(12): 601-4.

7. Xu J, Latif S, Wei S. Metastatic renal cell carcinoma presenting as gastric polyps: A case report and review of the literature. Int J Surg Case Rep. 2012;3(12):601-4.

8. Namikawa T, Muneke M, Kitagawa H, Okabayashi T, Kobayashi M, Hanazaki K. Metastatic gastric tumors arising from renal cell carcinoma: Clinical characteristics and outcomes of this uncommon disease. Oncol Lett. 2012;4(4): 631-636.

9. Gómez-de-la-Cuesta S, Fernández-Salazar L, Velayos-Jiménez B, Macho-Conesa A. Gastric metastasis from renal cell carcinoma Rev Esp Enferm Dig. 2012; 104(6): 334-5.

10. Kumcu E, Gönültas M, Ünverdi H, Hüctümenoğlu S. Gastric metastasis of a renal cell carcinoma presenting as a polypoid mass. Endoscopy. 2014;46(S 01): E464

118

119

120

121

122

123

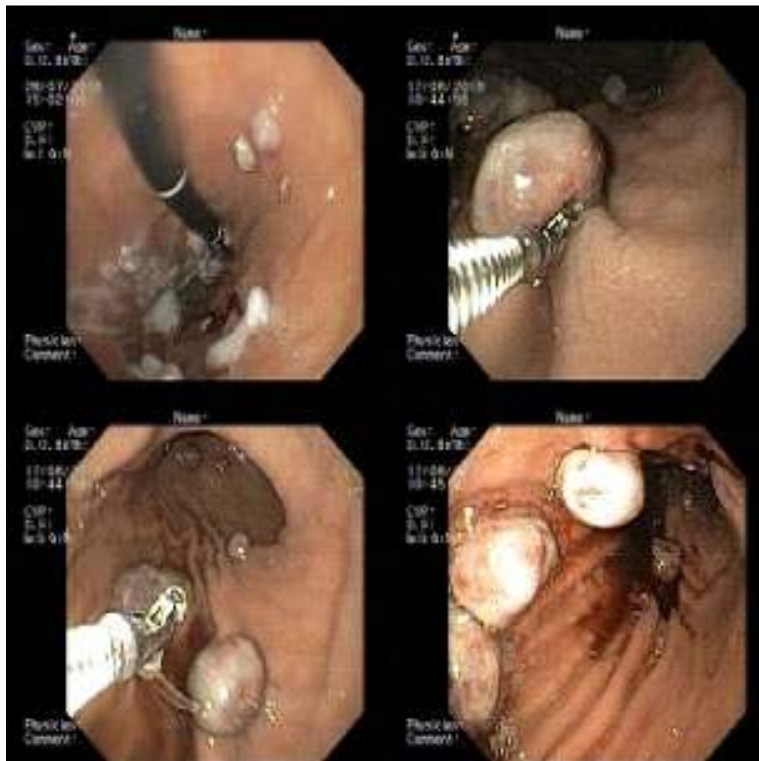124

125

126

127

128



129

130 **Figure 1: Multiple, polypoid masses in the corpus of stomach.**

131

132

133

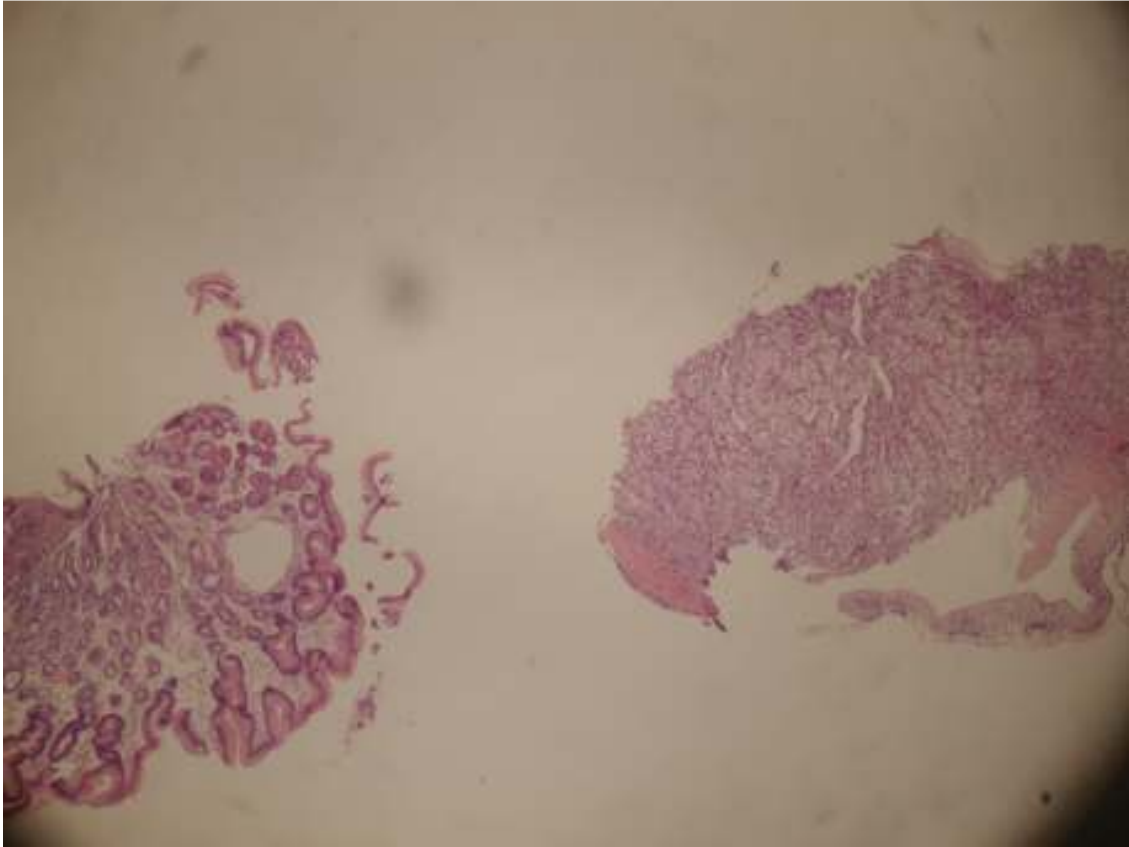
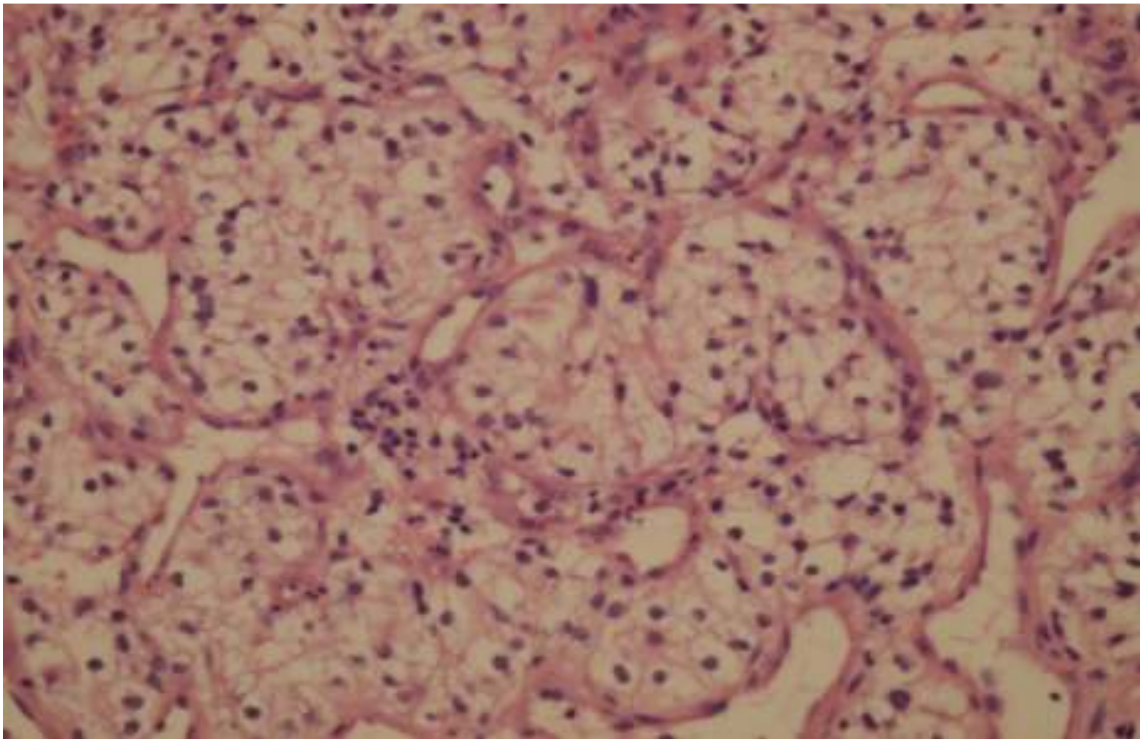
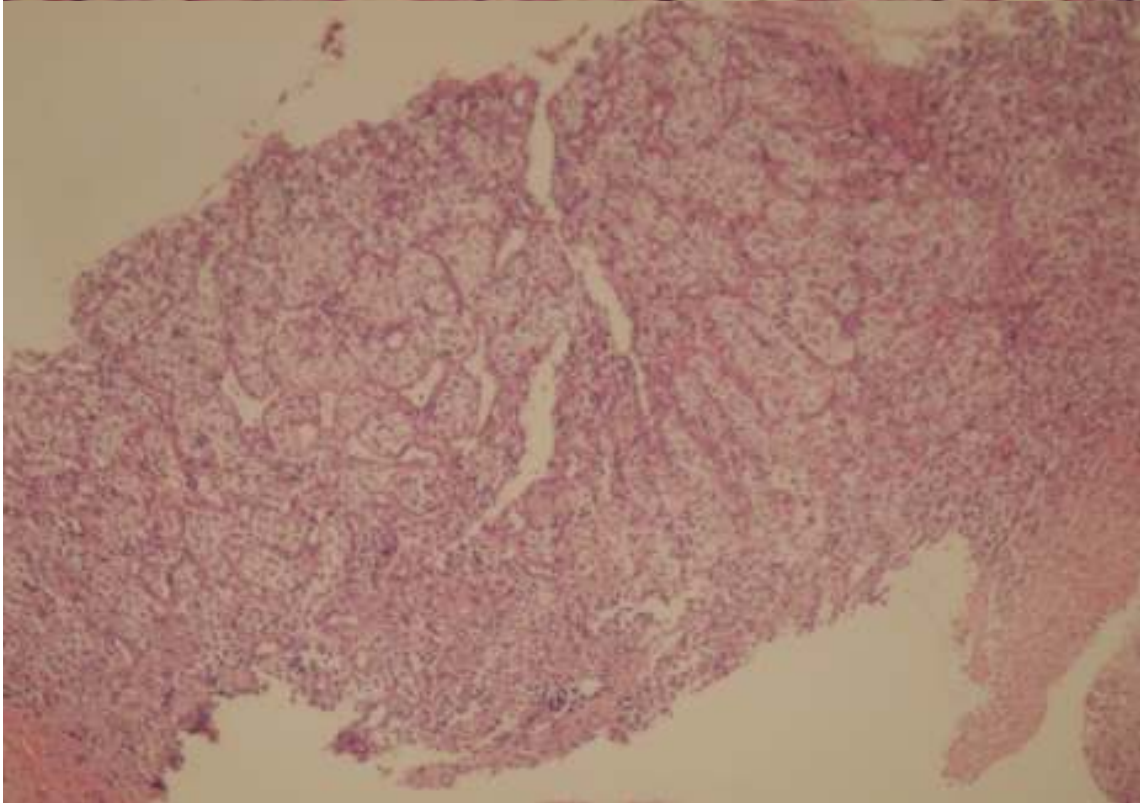


Figure 2: Biopsies from normal gastric mucosa and metastatic mucosa (H&E, 10X)



147



148

149 Figure 3: Submucosal nodular collections of epithelioid clear cells, typical histologic
150 characteristics of RCC in gastric mucosa (H&E, original magnification 40X and 100X).

151

