UNDER PEER REVIEW

Case Study

Right atrial myxoma complicated by pulmonary thromboembolism: A case report and review of literature

ABSTRACT

Primary cardiac tumors are rare with myxoma being the most common benign cardiac tumor. They are usually sporadic, affecting left atrium and frequently occur in women. They are known to cause valvular obstruction, thromboembolism and arrhythmias. We present a case of right atrial myxoma complicated by pulmonary embolism which proved fatal only to be diagnosed on autopsy.

Keywords: Myxoma; cardiac; atrial; embolism; pulmonary

1. INTRODUCTION

Primary cardiac tumors are rare; they are about 20 times less frequent than the secondary tumors of the heart [1]. The prevalence of cardiac tumors at autopsy has been reported to range from 0.001% to 0.3% [2]. A majority of primary cardiac tumors are benign; more than half being myxomas. Myxomas of the heart occur at all ages and have a greater prevalence in females [3]. Sporadic cardiac myxomas outnumber the familial ones and often arise from the left atrium [4,5]. Catastrophic outcome may be consequent upon systemic or pulmonary embolism or due to intracardiac obstruction. Prompt and early diagnosis is quintessential for timely surgical removal

UNDER PEER REVIEW

of myxomas to reduce morbidity and mortality [6]. A case report of right atrial myxoma with pulmonary thromboembolism is reported which caused sudden death and was diagnosed at autopsy.

2. CASE REPORT

The indexed case was a 21-year-old unmarried female who was brought dead to the hospital with information of sudden death as reported by the family. No other history or tests were available. A partial autopsy was performed and heart, portions of both lungs and uterus with bilateral adnexae were submitted for histopathology and toxicological analysis.

Heart weighed 270 gram and measured 12 x 10 x 7.5 cm. The right and left ventricular wall thickness measured 0.5 cm and 1.3 cm respectively. The valve circumferences of aortic, pulmonary, mitral and tricuspid valves were 5.5 cm, 6.0 cm, 8cm and 9.4 cm respectively. The right atrium showed a pedunculated grey tan to grey white nodule measuring 1.5 x 1 x 0.4 cm. The cut section was soft and had a gelatinous consistency. Both the coronaries were traced as far as possible and the lumina were found to be patent. Portions from both the lungs were also examined. Their cut surfaces were slate grey and unremarkable.

Uterus with bilateral adnexa was examined grossly and did not show any pathological change.

Sections examined from the nodule right atrium showed an endothelium-lined tumor composed of proliferating blood vessels and a few stellate shaped cells in a myxoid stroma (Figure 1). Mild lymphomononuclear cell infiltrate was also seen. Fibrinoid necrosis was seen on the surface of the tumor. Sections from rest of the heart were devoid of any pathological change. Both the coronaries showed age-related atherosclerotic changes.

UNDER PEER REVIEW

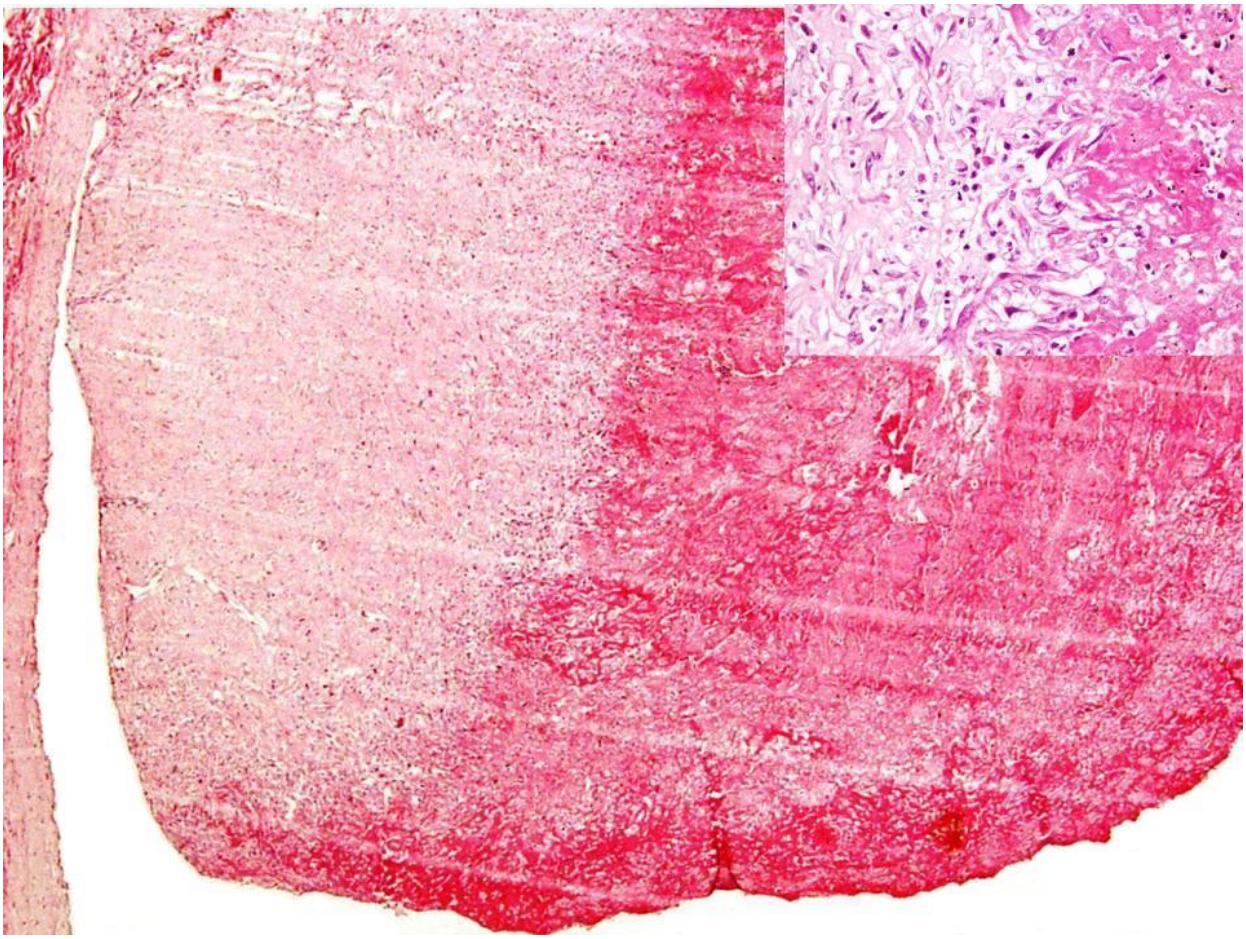

Figure 1: Photomicrograph showing endothelium-lined tumor composed of proliferating blood vessels in a myxoid stroma along with fibrinoid necrosis (H&E, x100). Inset shows stellate shaped cells admixed with few lymphomononuclear cells and necrosis (H&E, x400).

Representative sections from bilateral lungs showed presence of emboli in pulmonary vasculature attached to the vessel wall (Figure 2). Many vessels showed congestion.

UNDER PEER REVIEW

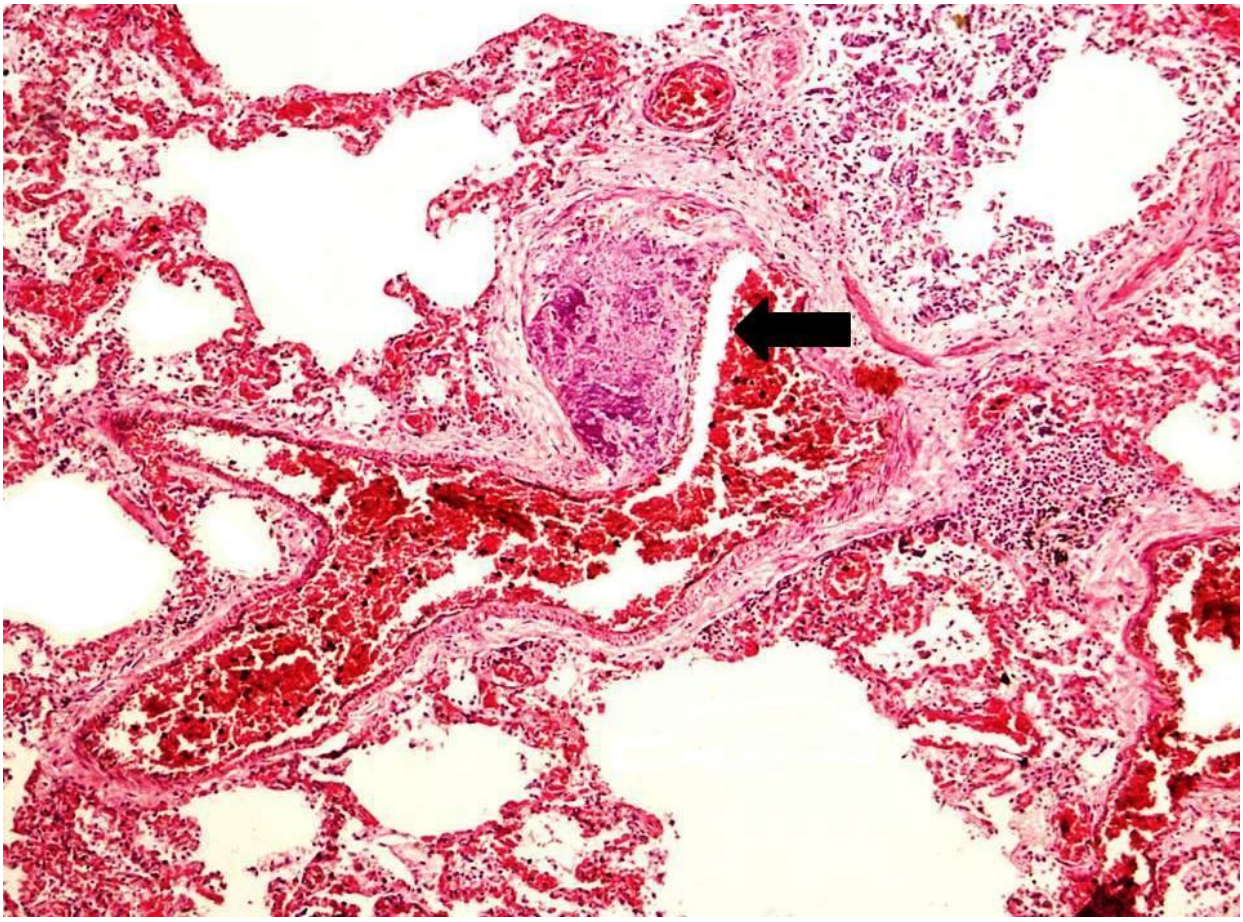

Figure 2: Section from the lung showing embolus in the pulmonary vasculature attached to the vessel wall (arrow) and many congested blood vessels (H&E, x100).

A histopathological diagnosis of right atrial myxoma with pulmonary thromboembolism was rendered. Uterus and adnexa did not show any microscopic pathologic change.

3. DISCUSSION

Cardiac myxomas account for 25% of all cardiac tumors and 50% of all benign cardiac tumors [7]. First case of cardiac myxoma in the right atrium was reported in 1908 and the association of pulmonary emboli with right atrial myxoma was first described in 1931 [6]. A vast majority of myxomas are sporadic which are usually solitary, frequent in older females and bear predilection

UNDER PEER REVIEW

for the left atrium. Carney et al [8] in 1985, described complex myxomas which are multiple, recurrent, with a familial tendency. Many associations with cardiac myxomas have been described that include simultaneous presence of myxomas at sites other than the heart, pigmented cutaneous lesions and endocrine disorders or neoplasms.

Myxomas of the heart arise from primitive mesenchymal cells present in the heart as entrapped embryonic remnants [1]. These multipotent mesenchymal cells have a capacity of epithelial and neural differentiation and proliferate to form myxomas. These cells produce vascular endothelial growth factor responsible for angiogenesis and growth of the tumor [2].

Cardiac myxomas are predominant in the left atrium (80%) followed by right atrium (15%), ventricles (3-4%), and rarely the valves [4]. Very rarely more than one cavity of the heart may be involved. Grossly, typical myxomas are polypoid, ovoid or papillary, pedunculated tumors with a gelatinous consistency. Tumors range from small to large with diameters varying from 1 to 15 cm [2]. The surface is smooth, villous or friable. Microsections show these tumors composed of scattered polygonal cells and immature endothelial cells embedded within abundant acid mucopolysaccharide stroma sprinkled with chronic inflammatory cells [1]. A peculiar observation is the presence of ill-formed vascular channels. Sometimes calcification may be seen which was not seen in the current case. On immunohistochemistry the tumor cells show positivity for vimentin and desmin.

Clinical manifestations of cardiac myxomas depend on the tumor size, site of location, mobility and friability [4]. Symptoms may be of valvular obstruction, pulmonary/systemic embolic phenomenon leading to syncope/sudden death at times, or non specific constitutional symptoms. Embolization has an estimated incidence of 30-40% and is more common with villous/papillary

UNDER PEER REVIEW

friable myxomas. The emboli may affect the brain, retina, coronary arteries, liver, spleen, kidney, abdominal aorta and the peripheral distal vasculature. Embolism is commonplace with myxomas located in the left atrium. It is seen in approximately 10% of the patients with myxoma in the right atrium and is usually not clinically evident, as in the present case with pulmonary microembolization diagnosed on autopsy [9].

A considerable delay in diagnosing cardiac myxoma occurs in a large number of patients due to lack of cardiac symptomatology or misleading extracardiac symptoms. Early treatment is necessary to avoid fatal complications due to intracardiac obstruction or embolization. The accepted modality of treatment of cardiac myxoma is adequate surgical excision with wide resection [4]. Pulmonary embolectomy should be considered in cases with pulmonary embolism [10]. The overall risk of recurrence is approximately 1-3% for sporadic myxoma [4]. The pulmonary embolism can recur after resection, the reported recurrence rate being 0.4% to 5% [9].

4. CONCLUSION

The right cardiac myxoma should be considered in the differential diagnosis of pulmonary embolism which is potential life threatening sequelae. Furthermore, when diagnosed ante-mortem or post-mortem, the family should undergo screening using the primary diagnosing modality, transthoracic echocardiography, to rule out familial cases albeit rare.

ETHICAL APPROVAL

Ethical approval is not applicable.

UNDER PEER REVIEW

REFERENCES

1. Manduz S, Katrancioglu N, Karahan O, Yucel O, Yilmaz MB. Diagnosis and follow up of patients with primary cardiac tumours: a single-centre experience of myxomas. Cardiovasc J Afr. 2011;22:310-2.

2. Cohen R, Singh G, Mena D, Garcia CA, Loarte P, Mirrer B. Atrial Myxoma: A case presentation and review. Cardiol Res. 2012;3:41-4.

3. Sun P, Wang ZB. Familial atrial myxoma. Cardiol Young. 2008;18:525-7.

4. Fabijanić D, Rudez I, Kardum D, Radić M, Glavas D, Lozo P. Pulmonary embolism due to the right atrial myxoma. Coll Antropol. 2006;30:933-6.

5. Edwards A, Bermudez C, Piwonka G, Berr ML, Zamorano J, Larrain E et al. Carney's syndrome: complex myxomas. Report of four cases and review of the literature. Cardiovasc Surg. 2002;10:264-75.

6. Battellini R, Bossert T, Areta M, Navia D. Successful surgical treatment of a right atrial myxoma complicated by pulmonary embolism. Interact Cardiovasc Thorac Surg. 2003;2:555-7.

7. Peters PJ, Reinhardt S. The echocardiographic evaluation of intracardiac masses: a review. J Am Soc Echocardiogr. 2006;19:230-40.

UNDER PEER REVIEW

8. Carney JA, Gordon H, Carpentier PCS, Sheney BV, Go VLM. The complex of myxomas, spotty pigmentation and endocrine overactivity. Medicine. 1985;64:270-83.

9. Jung J, Hong YS, Lee CJ, Lim SH, Choi H, Lee S. Successful surgical treatment of a right atrial myxoma complicated by pulmonary embolism. Korean J Thorac Cardiovasc Surg. 2013;46:63-7.

10. Keenan DJ, Morton P, O'Kane HO. Right atrial myxoma and pulmonary embolism. Rational basis for investigation and treatment. Br Heart J. 1982;48:510-2.