Original Research Article

Effect of curcumin on aflatoxin B_1–induced toxicity in rats: A Biochemical and histopathological study

ABSTRACT

Objective: The aim of the present study was to investigate the protective effect of curcumin against aflatoxin B_1 (AFB_1) induced hepatotoxicity.

Materials and Methods: Twenty-eight healthy adult male Wistar rats were divided into four groups. Rats of the first group received basal diet and served as control. Rats in the second group received curcumin orally (15mg/5ml/kg body weight) whereas, rats in the third groups injected with single intraperitoneal injection of AFB_1 (3mg/kg BW). Rats in the fourth group received a combination of second and third groups for five weeks.

Results: Biochemical analysis of serum samples indicated a significant increase in aspartate transaminase (AST) and alanine transaminase (ALT) activities and total cholesterol and creatinine concentrations along with significant decrease in protein content of AFB_1 intoxicated rats compared to control group. Oral administration of curcumin along with injected AFB_1 restored AST, ALT, total cholesterol, creatinine and total protein near to control values. Biochemical analysis of liver antioxidants revealed a significant ($P < 0.05$) reduction in catalase (CAT) and superoxide dismutase (SOD) activities and hepatic reduced glutathione (GSH) content in rats injected with AFB_1 compared to control. On the contrary, oral administration of curcumin along with injected AFB_1 enhanced hepatic CAT and SOD activities and GSH concentration towards the control values, suggesting that curcumin could improve the antioxidant status in AFB_1 induced oxidative stress. The Biochemical findings were supported by histopathology of liver tissues which indicated vacuolar degeneration and necrotizing

changes in liver of rats intoxicated with AFB_1 and significant amelioration of these effects in these rats whenever treated with curcumin.

Conclusion: Conclusively, oral administration of curcumin along with AFB_1 caused significant inhibition in AFB_1-induced hepatotoxicity in rats by increasing the concentration of GSH and activation of antioxidant enzymes.

Keywords: Medicinal plants, Antioxidants, Oxidative stress, Biomarkers, liver

1. INTRODUCTION

Mycotoxins are toxic metabolites produced by a large number of fungi under a wide range of environmental condition. Many of these fungi invade cereals, nuts and grains that are eventually used in the manufacture of animal feeds. Aflatoxins are secondary metabolites of the moulds *Aspergillus flavus, Aspergillus parasiticus, Aspergillus tamarii* and *Aspergillus nominus* [1]. AFB_1 is by far the most potent teratogen, mutagen and hepatocarcinogen of all aflatoxins [2]. The carcinogenic potential of AFB_1 following oral administration has been shown in several animal species, including rodents, non-human primates and fish [3]. The biological effects of AFB_1 in animals are related to their level in the feed and to the animal's susceptibility. Epidemiologic, clinical, and experimental studies have revealed that aflatoxins are hepatotoxic, hepatocarcinogenic, and mutagenic [4]. AFB_1 can cause lipid peroxidation in the rat liver, which is closely related to liver cell injury [5,6]. Bosch-Morell et al. [7] have demonstrated the involvement of oxidative stress in retinal detachment by detecting lipid peroxidation products in subretinal fluid of patients undergoing surgery. Medicinal plants and their active principles had received great attention as potentially antiperoxidative agents [8-15]. Turmeric is a perennial herb that grows to a height of three to five feet and is cultivated extensively in Asia (India and China) and other

countries with tropical climate. Curcumin, the active ingredient from the spice turmeric is a potent antioxidant and anti-inflammatory agent with hepatoprotective, anticarcinogenic and antimicrobial properties [16]. In addition, gene expression of antioxidant enzymes has been up-regulated by curcumin in diabetic rats [15]. Although, the antitoxic effect of curcumin has been investigated [10,12], the literature reports are still contradictory. Therefore, the objective of the present study was to investigate the antitoxic effect of curcumin in AFB_1 intoxicated rats by evaluation of selected serum biochemical parameters, hepatic oxidative stress biomarkers and histopathology of affected liver.

2. MATERIALS AND METHODS

2.1. Chemicals

Curcumin, AFB1 and DMSO were purchased from Sigma Chemical Co. (St. Louis, MO, USA). All other chemicals and buffers were of analytical grade.

2.2. Experimental animals

Twenty-eight healthy adult male inbred Wistar rats weighing between 150–200g were obtained from the laboratory animal house of the Faculty of Veterinary Medicine and Animal Recourses, King Faisal University, Saudi Arabia. They were maintained in accordance with the national guidelines and protocols, approved by the University Animal Ethics Committee, King Faisal University, Saudi Arabia. They were housed in clean and disinfected plastic cages. Commercial basal pelleted diet and water were provided *ad libitum.* Rats were subjected to natural photoperiod of 12hr light:dark cycle throughout the experimental period (5 weeks). The experimental animals were housed in air-conditioned rooms at 21-23°C and 60-65% of relative humidity. All rats received

basal diet for two weeks before the start of the experiment for adaptation and to ensure normal growth and behavior.

2.3. Experimental design

Rats were divided into four groups of 7 rats each (4 animals/cage). Rats of the first group received basal diet and served as normal control (NC). Rats in the second group received curcumin orally (15mg/5ml/kg BW) [15] and labeled as curcumin treated group (CT) whereas, rats in the third groups injected with single i.p injection of AFB_1 dissolved in dimethyl sulphoxide DMSO (3mg/kg BW) [17] and labeled as AFB_1 treated group (AF) for five weeks. Rats in the fourth group received a combination of second and third groups and labeled as AFB_1 + curcumin treated group (AC) for also five weeks.

2.4. Sampling and analysis

At the end of the experiment, rats were sacrificed, anaesthetized by diethyl ether inhalation and blood and liver samples were collected. Serum was separated by centrifugation for 10 min at 1200g and was immediately frozen at –20ºC until the time of analysis.

2.4.1. Glucose and protein assays

Commercial diagnostic kits (United Diagnostic Industry, UDI, Dammam, Saudi Arabia) were used for determination of glucose (EP37L-660), total proteins (EP56-660) and albumin (EP03-570).

2.4.2. Lipid profile and liver enzyme tests

The kits (United Diagnostic Industry, UDI, Dammam, Saudi Arabia) were used for determination of triacylglycerol, TAG (EP59-660), total cholesterol (EP24-660), alanine aminotransferase, ALT (EP07-500) and aspartate amino transferase AST (EP15-500).

2.4.3. Kidney function tests

Blood urea nitrogen, BUN (EP20-420), uric acid (EP61-620) and creatinine (EP33K-660) were also estimated by commercial kits of the same company (United Diagnostic Industry, UDI, Dammam, Saudi Arabia).

2.4.4. Electrolyte test

Kits of United Diagnostic Industry, UDI, Dammam, Saudi Arabia were used for estimation of calcium (EP22-660), phosphorus (EP46-660), magnesium (EP50-660), and chloride (EP27-500) on ELIPSE full automated chemistry analyzer (Rome, Italy). Concentration of the biochemical constituents was calculated according to the manufacturer's instructions.

2.4.5. Assay of oxidative stress biomarker

Portion of the liver was dissected out and trimmed off the attached tissue and stored at –80ºC until used for biochemical analysis of GSH concentration and antioxidant enzyme activities. The activities of CAT (nmol/min/gram tissue; Cayman Chemical Company, USA, Catalog No. 707002), total SOD (U/ gram tissue; Cayman Chemical Company, USA, Catalog No. 706002) and concentrations of GSH (µM/ gram tissue; Cayman Chemical Company, USA, Catalog No.703002) were determined by ELISA reader (Absorbance Microplate Reader ELx 800TM BioTek®, USA). The buffer for

preparation of liver tissues homogenate were obtained from Cayman Chemical Company, USA. Results were calculated according to the manufacturer's instructions.

2.4.6. Histopathological study

Another portion of liver tissue was collected also and cut in small pieces and immersed in neutral buffered formalin for 24 h for histopathological examination. The fixed liver tissue was processed routinely, embedded in paraffin, sectioned, deparaffinized and rehydrated using the standard techniques [18]. The effect of high cholesterol diet and the ameliorative effect of curcumin was evaluated by assessing the morphological changes in the liver sections stained with hematoxylin and eosin (H and E), using standard techniques.

2.5. Statistical analysis

All the grouped data were statistically evaluated and the significance of changes caused by various treatments was determined using one ways ANOVA. Post hoc tests in the Analysis of Variance (ANOVA), containing one factor (Group) and serum biochemical dependent measurements, was used applying GLM- Unianova Procedure. Bartlett's, Brown and Forsythe's Tests for Homogeneity of Variance assumptions were reasonably met for the one way ANOVA. The tables (1-5) shows the significance difference of means and all tests were performed using computer package of the statistical analysis system (SAS) [19].

3. RESULTS

3.1. Selected Biochemical Parameters

The present findings indicated that, AFB_1 treatment (AT) induced significant increase ($P < 0.05$) in total cholesterol, ALT and AST activities (Table 2) and creatinine concentration (Table 3) however protein contents (Table 1) was significantly decreased ($P \leq 0.05$) in serum of rats when compared with the normal control group (NC). Oral administration of curcumin along with injected AFB_1 (AC) restored total cholesterol, ALT, AST, creatinine and total protein near to control values.

3.2. Oxidative stress Biomarkers

The effects of AFB_1 and curcumin either alone (CT) or in combination (AC) on oxidative stress biomarkers of liver tissues of rats are summarized in Table 5. A significant ($P < 0.05$) reduction of CAT and SOD activities and GSH content were evident in rats injected with AFB_1 (AT) compared to normal control animals (NC). On the contrary, Oral administration of curcumin along with AFB_1 (AC) caused significant amelioration in AFB_1-induced effects observed by decreased CAT and SOD enzymes activities ($P \leq 0.05$) and increased reduced glutathione contents ($P \leq 0.001$) compared to the AFB_1 treated rats (AT).

3.3. Histopathological examination

Liver of the normal control (NC) and curcumin treated rats (CT) showed central veins surrounded by polygonal cells arranged in regular cords separated from each other by sinusoids (Fig. 1A). The liver of rats intoxicated with AFB_1 (AT) showed distorted lobular architecture and necrobiotic changes ranged from vacuolar degeneration to necrotizing changes. This was associated with mononuclear cell infiltration everywhere (Fig. 1B). However, livers treated with AFB_1 along with curcumin (AC) appeared more or less recovered and have an almost normal architecture (Fig. 1C).

4. DISCUSSION

4.1. Selected Biochemical parameters

It is well known that, aflatoxin has a harmful and stressful effect on liver tissue. AST and ALT are cytosolic enzymes and are famous biomarkers of liver damage. In the present study, AFB_1 injection (AT) was found to cause an increase in serum ALT and AST activities (Table 2). These results indicated liver injury and necrosis [20,21]. Whenever liver was injured, levels of hepatic transaminases were significantly increased [22-24]. However, administration of curcumin along with injected AFB_1 (AC) showed marked recovery but still beyond the ALT and AST levels (Table 2) of control group. Regarding the ameliorative effect of curcumin against AFB_1 toxicity, previous reports [25,26] showed a significant hepatoprotective activity of curcumin by lowering the level of serum biomarker enzymes in AFB1 intoxicated rats. Low total protein level acts as an indicator of the toxic effect of AFB_1 in serum [27]. Aflatoxin is known to impair protein biosynthesis by forming adducts with DNA, RNA and proteins, inhibits RNA synthesis, DNA-dependent RNA polymerase activity and causes degranulation of endoplasmic reticulum [27]. Reduction in protein content (Table 1) observed in the current study (AT) may be attributed to increase in the rate of degeneration of liver tissues as underlined by increasing activities of ALT and AST (Table 2). The injured liver logically is unable to maintain vital biochemical processes particularly protein biosynthesis. These results are in accordance with previous work [28] which reported a decrease in protein content in skeletal muscle, heart, liver and kidney of aflatoxin-fed animals. The present results showed that, curcumin treatment along with injected AFB_1 (AC) ameliorates AFB_1-induced changes in protein contents in the serum of rats (Table 1). The amelioration in protein contents might be due to increased DNA synthesis and reduction in harmful adduct formation [29]. Authors investigated the inhibitory effects

of curcumin, garlic squeeze, grape seed extract, tea polyphenols, vitamin C and vitamin E on nicotine-DNA adduction *in vivo*. They suggested that these dietary constituents are beneficial in preventing the harmful adduct formation and thus block the potential carcinogenesis induced by nicotine. Similar results described the ameliorative effect of curcumin against AFB1 induced low protein contents in Broiler chicks [30] and in mice [31]. After biosynthesis of creatine in the liver, it is taken up from the blood by skeletal muscles and converted into creatine phosphate. Creatine and its phosphate are converted spontaneously into creatinine [32]. The significant appearance ($P < 0.05$) of creatinine in the serum of aflatoxin-fed rats indicated the increased transformation of phosphocreatine to creatinine in muscle which might be due to lesser utilization of phosphocreatine in muscular contraction. The elevated creatinine level in AFB_1 treated (AT) rats as observed in the current study, suggests the myotoxic and nephrotoxic effect of AFB_1 in rats [33] which improved upon administration of curcumin.

4.2. Oxidative stress Biomarkers

Oxidative stress was originally defined as the imbalance between prooxidants and antioxidants in biological systems. The significant reduction in the activities of enzymatic antioxidants such as CAT and SOD as well as non- enzymatic antioxidants such as glutathione in the liver of AFB_1-treated rats (AT) when compared to the NC and CT groups (Table 5) indicated that AFB_1 induced oxidative stress and subsequent liver damage. SOD protects cells from oxidative damage by converting free radical superoxide to H_2O_2 and O_2. The H_2O_2 produced can then be decomposed enzymatically by CAT. Significant reductions in SOD [27] and CAT [24] have been reported in aflatoxin-fed rat liver. The significant increase of hepatic antioxidant enzymes CAT and SOD activities observed in this study in rats intoxicated with AFB1 and treated with

curcumin (AC) (Table 5) are in accordance with previous studies which reported that curcumin is a potent inducer of detoxifying enzymes and thereby prevents the toxicity induced by a chemical carcinogen [15,34]. Glutathione has a beneficial effect by virtue of possessing –SH groups. It helps to protect biological membranes, which are readily susceptible to peroxidation. Carcinogens like AFB_1, which generate epoxides, have been found to conjugate readily with GSH. Lower GSH level would further aggravate the toxic effects of aflatoxin. Many investigators [27, 35] have reported significant reduction in glutathione content in aflatoxin-fed rat liver. The impact of curcumin on GSH has been documented [15].

4.3. Histopathological findings

The histopathological findings (Figure 1) supported the biochemical findings and give evidence of liver damage in rats intoxicated with AFB_1 (AT). Similar AFB_1-induced hepatic damage has been reported [36]. The relief of hepatic tissues in AFB_1 intoxicated rats treated with curcumin (AC) is consistent with earlier report [25] which suggested that curcumin but not resveratrol has a hepatoprotective effect against aflatoxin B(1)-induced liver injury.

5. CONCLUSION

The results obtained in this study indicated that, AFB_1 administration induced hepatotoxicity in rats as reflected on elevation of hepatic transaminases, reduction of antioxidant enzymes activities and reduction of glutathione concentration in serum and necrosis of liver tissues. Oral administration of curcumin along with AFB_1 caused significant amelioration in AFB_1-induced hepatotoxicity in rats by increasing the

concentration of GSH and activation of antioxidant enzymes. This suggests that curcumin could improve the antioxidant status in AFB_1-induced oxidative stress.

REFERENCES

1. Goto T, Wicklow DT, Ito Y. Aflatoxin and cyclopiazonic acid production by a sclerotium-producing *Aspergillus tamarii* strain. Appl Environ Microbiol. 1996;62:4036–4038.
2. Busby W, Wogan G. Aflatoxins. Chemical carcinogens. Am Chem Soc Monogr. 1984;2:954–1136.
3. Roebuck BD, Maxuitenko YY. Biochemical mechanisms and biological implications of the toxicity of aflatoxins as related to aflatoxin carcinogenesis. In: Eaton DL and Groopman JD, editors. The Toxicology of Aflatoxins. Academic Press, San Diego. 1994;27–43.
4. Pohland E. Mycotoxins in review. Food Addit. Contam. 1993;10:17–28.
5. Shen HM, Shi CY, Lee HP, Ong CN. Aflatoxin B_1-induced lipid peroxidation in rat liver. Toxicol Appl Pharmacol. 1994; 127:145–150.
6. Shen HM, Ong CH, Lee BL, Shi CY. Aflatoxin B_1 induced 8-hydroxide-oxyguanosine formation in rat hepatic DNA. Carcinogenesis. 1995;16:419–422.
7. Bosch-Morell F, Sanz A, Diaz-Llopis M, Romro FJ. Lipid peroxidation products in human subretinal fluid, Free Radic Biol Med. 1996;20:899–903.
8. Lee BM, Park KK. Beneficial and adverse effects of chemopreventive agents. Mutat Res. 2003;270:523-524.
9. El-Bahr SM. Effect of black cumin seeds (*Nigella sativa*) on the profile of serum lipids, lipoproteins and fatty acids in pekin ducklings. International Journal of Applied Chemistry. 2007;3: 221–230.

10. El-Bahr SM, Korshom MA, Mandour AA, El-Bessomy AA, Lebdah MA. The protective effect of Turmeric on iron overload in albino rats. Egyptian journal of biochemistry and molecular biology. 2007;25: 94-113
11. El-Bahr SM, Saad TT. Effect of Black cumin seeds (*Nigella sativa)* and/or Turmeric *(Curcumin*) on hematological, biochemical and Immunological parameters of *Mugil cephalus* fish vaccinated with *Aeromonus hydrophila* bacterin. The Thirteen scientific congress, Faculty of Veterinary Medicine, Assuit University, 25-28, November. 2008;365-388.
12. Salama AF, El-Bahr SM. Effect of curcumin on cadmium-induced oxidative testicular damage in rats. Journal of Medical Research Institute. 2007;28: 167-173.
13. Al-Nazawi MH, El-Bahr SM. Hypolipidemic and hypocholestrolemic effect of medicinal plant combination in the diet of rats: Black cumin seed (*Nigella sativa*) and Turmeric (*Curcumin*). J Anim Vet Adv. 2012;11(12):2013-2019.
14. Abdelwahab AM, El-Bahr SM. Influence of Black Cumin Seeds (*Nigella sativa*) and Turmeric (*Curcuma longa Linn.*) Mixture on Performance and Serum Biochemistry of Asian Sea Bass, *Lates calcarifer*. World Journal of Fish and Marine Sciences. 2012;4(5):496-503.
15. El-Bahr SM. Curcumin regulates gene expression of insulin like growth factor, B-cell CLL/lymphoma 2 and antioxidant enzymes in streptozotocin induced diabetic rats. BMC Complementary and Alternative Medicine, 2013;13:368-379.
16. Pal S, Choudhuri T, Chattopadhyay S, Bhattacharya A, Datta GK, Das T, Sa G. Mechanisms of Curcumin induced apoptosis of Ehrlich's ascites carcinoma cells. Biochem Biophys Res Commun. 2001;288:658-665.

17. Kamdem L, Magdalou J, Siest G, Ban M, Zissu D. Induced hepatotoxicity in female rats by aflatoxin B1 and ethynylestradiol interaction. Toxicol Appl Pharmacol. 1983;67:26-40.
18. Bancroft, J.D., Gamble, M.,. Theory and Practice of Histological Techniques. 5th ed. Churchill Livingstone, New York, USA; 2002
19. Chou YH. Experimental design and the analysis of variance, Statistical Analysis-I. New York: Holt, Reinhart and Winston Publication; 1975;340-352.
20. Abdel-Wahhab MA, Aly SEJ. Antioxidants and radical scavenging properties of vegetable extracts in rats fed aflatoxin-contaminated diet. Agric. Food Chem. 2003;51:2409-2414.
21. Farombi EO, Adepoju BF, Ola-Davies OE, Emerole GO. Chemoprevention of aflatoxin B1-induced genotoxicity and hepatic oxidative damage in rats by kolaviron, a natural biflavonoid of *Garcinia kola* seeds. Eur J Cancer Prev. 2005;14:207-214.
22. Koul IB, Kapil A. Effect of diterpenes from *Andrographis paniculata* on antioxidant defense system and lipid peroxidation. Ind J Pharmacol. 1994;26:296-300.
23. Trivedi N. 1999. Effect of radiomimetic plant on vital organ. Ph.D. thesis, Gujarat University, Ahmedabad, India.
24. Mathuria N, Verma RJ. Curcumin ameliorates aflatoxin-induced lipid-peroxidation in liver and kidney of mice. Acta Pol Pharm. 2008;65:195–202.
25. El-Agamy D. Comparative effects of curcumin and resveratrol on aflatoxin B1 induced liver injury in rats. Arch Toxicol. 2010;84:389–396.
26. Nayak S, Sashidhar RB. Metabolic intervention of aflatoxin B1 toxicity by curcumin. J Ethnopharmacol. 2010;127:641–644.

27. Cullen JM, Newberne PM.. Acute hepatotoxicity of aflatoxins. In: Eaton DL and Groopman JD, editors. The Toxicology of Aflatoxins. Academic Press, San Diego. 1994;3-26.
28. Quezada T, Cuellar H, Jaramillo-Juarez F, Valdivia AG, Reyes JL. Effects of aflatoxin B(1) on the liver and kidney of broiler chickens during development. Comp Biochem Physiol C Toxicol Pharmacol. 2000;125:265-272.
29. Cheng Y, Li HL, Wang HF, Sun HF, Liu YF, Peng SX, et al. Inhibition of nicotine-DNA adducts formation in mice by six dietary constituents Food Chem Toxicol. 2003;41:1045-1050.
30. Gowda NKS, Ledoux DR, Rottinghaus GE, Bermudez AJ, Chen YC. Efficacy of Turmeric (*Curcuma longa*), Containing a Known Level of Curcumin, and a Hydrated Sodium Calcium Aluminosilicate to Ameliorate the Adverse Effects of Aflatoxin in Broiler Chicks. Poult Sci. 2008;87:1125–1130.
31. Sharma V, Sharma C, Paliwal R, Pracheta, Sharma S. Ameliorative effects of curcuma Longa and curcumin on aflatoxin B1 induced serological and biochemical Changes in kidney of male mice. Asian J Biochem Pharmaceut Res. 2011;2:338-351.
32. McLauchlan DM. Creatinine, Urate and Urea. In: Gowenlock AD, editor. Varley`s Practical Clinical Biochemistry. Heinemann Medical Books, London. 1988;350.
33. Verma RJ, Raval PJ. Nephrotoxicity during aflatoxicosis. Med Sci Res. 1997;25:655-657.
34. Singletary K, Mac Donald C, Lovinelli M, Fisher C, Wallig M. Effect of the beta-diketones diferuloylmethane (curcumin) and dibenzoylmethane on rat

mammary DNA adducts and tumors induced by 7,12-dimethylbenz[a]anthracene. Carcinogenesis. 1998;19:1039-1043.

35. Emadi M, Kermanshahi H. Effect of Turmeric Rhizome Powder on the Activity of Some Blood Enzymes in Broiler Chickens. Int J Poult Sci. 2007;6:48-51.
36. Abdel-Wahab MA, Hassan NS, El-Kady AA, Khadrawy YA, El-Nekeety AA, Mohamed SR, Sharaf HA, Manna FA. Red ginsing extract protects against aflatoxin B1 and fumonisins-induced hepatic pre-cancerous lesions in rats. Food Chem Toxicol. 2010;48:733-742.

Table 1. Effect of oral administration of AFB_1 and/or curcumin for five weeks on serum glucose and proteins patterns of rats

Parameters	Groups	N	Mean	SEM	95% Confidence Limits		
					Lower	Upper	
Glucose (mmol/l)	I	7	7.967	0.606	6.35	9.58	a
	II	7	8.767	0.788	7.15	10.38	a
	III	7	8.267	0.546	6.65	9.88	a
	IV	7	8.533	0.825	6.92	10.15	a
Total proteins (g/l)	I	7	6.567	0.484	4.91	8.22	a
	II	7	6.800	0.723	5.14	8.46	a
	III	7	5.100	0.608	3.60	6.60	b
	IV	7	6.800	0.757	5.14	8.46	a
Albumin (g/l)	I	7	4.400	0.551	3.04	5.76	a
	II	7	4.467	0.636	3.10	5.83	a
	III	7	3.000	0.577	1.65	4.35	a
	IV	7	4.333	0.570	2.97	5.70	a
Globulin (g/l)	I	7	3.100	0.493	1.73	4.47	a
	II	7	2.770	0.233	1.40	4.14	a
	III	7	2.100	0.058	1.12	3.08	a
	IV	7	3.500	0.651	2.13	4.87	a
Albumin/globulin ratio	I	7	1.570	0.088	1.30	1.84	a
	II	7	1.600	0.115	1.33	1.87	a
	III	7	1.430	0.260	1.07	1.80	a
	IV	7	1.600	0.100	1.33	1.87	a

I (control), II (curcumin treated rats), III (AFB_1 treated rats), IV (AFB_1 + curcumin treated rats), Means with the same letter are not significantly different ($P > 0.05$)

Table 2. Effect of oral administration of AFB_1 and/or curcumin for five weeks on serum lipid profile and hepatic transaminases of rats

Parameters	Groups	N	Mean	SEM	95% Confidence Limits		
					Lower	Upper	
Total cholesterol (mmol/l)	I	7	2.10	0.493	1.03	3.17	a
	II	7	2.33	0.524	1.27	3.40	a
	III	7	3.87	0.186	2.87	4.86	b
	IV	7	2.17	0.441	1.10	3.23	a
TAG (mmol/l)	I	7	2.00	0.289	1.32	2.68	a
	II	7	2.07	0.318	1.38	2.75	a
	III	7	2.03	0.273	1.35	2.72	a
	IV	7	2.10	0.306	1.42	2.78	a
ALT (U/l)	I	7	18.33	0.882	15.96	20.70	a
	II	7	18.67	0.882	16.30	21.04	a
	III	7	28.00	1.155	25.63	30.37	b
	IV	7	22.00	1.155	19.63	24.37	c
AST (U/l)	I	7	110.00	2.887	104.74	115.26	a
	II	7	111.00	2.082	105.74	116.26	a
	III	7	150.33	2.603	145.08	155.59	b
	IV	7	120.00	1.155	114.74	125.26	c

TAG: triacylglycerol; ALT: alanine transaminase; AST: aspartate transaminase;

Means with the same letter are not significantly different ($P > 0.05$)

Table 3. Effect of oral administration of AFB_1 and/or curcumin for five weeks on kidney function test of rats

Parameters	Groups	N	Mean	SEM	95% Confidence Limits		
					Lower	Upper	
BUN(mmol/l)	I	7	1.333	0.120	1.12	1.55	a
	II	7	1.333	0.088	1.12	1.55	a
	III	7	1.367	0.067	1.15	1.58	a
	IV	7	1.333	0.088	1.12	1.55	a
Uric acid(mmol/l)	I	7	124.000	3.055	116.59	131.41	a
	II	7	125.000	2.887	117.56	132.38	a
	III	7	126.300	3.152	118.86	133.68	a
	IV	7	124.600	3.700	117.19	132.01	a
Creatinine (mmol/l)	I	7	52.700	1.453	48.92	56.41	a
	II	7	53.000	1.528	49.25	56.75	a
	III	7	123.300	1.764	119.59	127.08	b
	IV	7	97.000	1.732	93.25	100.75	c

BUN: blood urea nitrogen

Means with the same letter are not significantly different (P> 0.05)

Table 4. Effect of oral administration of AFB_1 and/or curcumin for five weeks on serum electrolytes concentrations of rats

Parameters	Groups	N	Mean	SEM	95% Confidence Limits		
					Lower	Upper	
Calcium(mmol/l)	I	7	2.700	0.379	1.67	3.73	a
	II	7	3.000	0.577	1.97	4.03	a
	III	7	3.200	0.441	2.14	4.19	a
	IV	7	3.300	0.351	2.27	4.33	a
Phosphorus(mmol/l)	I	7	0.967	0.145	0.50	1.44	a
	II	7	1.100	0.208	0.63	1.57	a
	III	7	1.067	0.219	0.60	1.54	a
	IV	7	1.067	0.233	0.60	1.54	a
Magnesium(mmol/l)	I	7	0.867	0.088	0.62	1.11	a
	II	7	0.833	0.120	0.59	1.08	a
	III	7	0.767	0.120	0.52	1.01	a
	IV	7	0.867	0.088	0.62	1.11	a
Chloride (mEq/L)	I	7	116.700	2.339	109.04	124.43	a
	II	7	115.000	2.887	107.30	122.70	a
	III	7	115.300	4.055	107.64	123.03	a
	IV	7	114.000	3.786	106.30	121.70	a

Means with the same letter are not significantly different (P> 0.05)

Table 5. Effect of oral administration of AFB_1 and/or curcumin for five weeks on oxidative stress biomarkers, GSH, CAT and SOD in liver tissues of rats

Parameters	Groups	N	Mean	SEM	95% Confidence Limits		
					Lower	Upper	
CAT (nmol/min/gram tissue)	I	7	35.33	1.45	32.28	38.38	a
	II	7	36.33	1.45	33.28	39.38	a
	III	7	29.00	1.15	25.95	32.05	b
	IV	7	35.67	1.20	32.62	38.72	a
SOD (U/gram tissue)	I	7	08.33	0.88	6.90	9.77	a
	II	7	08.67	0.67	7.23	10.10	a
	III	7	05.00	0.58	3.56	6.44	b
	IV	7	08.00	0.00	6.56	9.44	a
GSH (µM/gram tissue)	I	7	07.33	0.33	6.67	8.00	a
	II	7	07.67	0.33	7.00	8.33	a
	III	7	05.33	0.33	4.67	6.00	b
	IV	7	08.00	0.00	7.33	8.67	a

I (control), II (Curcumin treated rats), III (AFB_1 treated rats), IV (AFB_1 + Curcumin treated rats),

CAT: catalase; SOD: superoxide dismutase; GSH: reduced glutathione

Means with the same letter are not significantly different (P> 0.05)

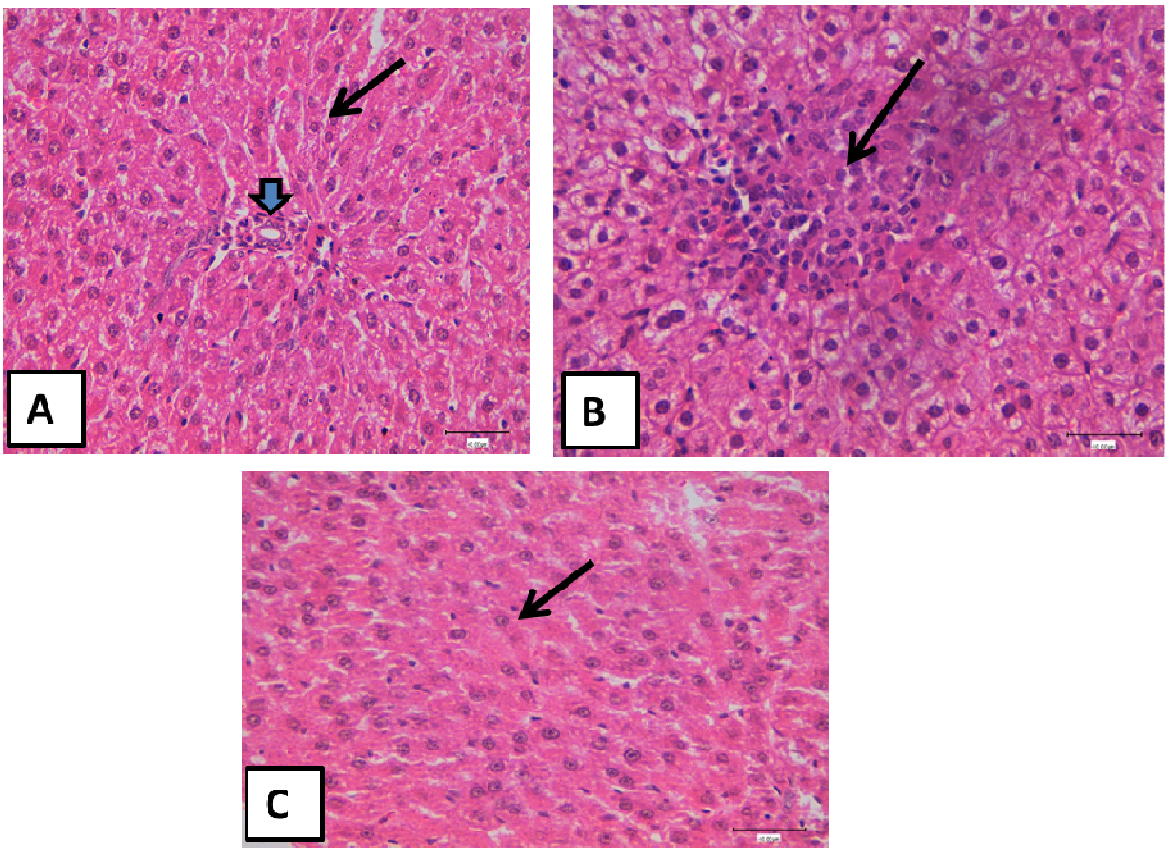

Fig.1 Histopathological findings of liver of rats administered of AFB1 and/or curcumin for five weeks (A) Liver of normal control rats (NC) and liver of curcumin treated rats (CT) showing the same normal portal area (arrowhead) and regular hepatic cords (arrow). (B) Liver of AFB1 treated rats (AF) showing vacuolar degeneration and foci of mononuclear cell infiltration (arrow). (C) Liver of AFB1 treated rats along with the curcumin (AC) seem to be normal and similar to control (arrow). HE bar= 40 µm.