

Botryoid Odontogenic Cyst: Case Report

Darin Johnston^{1*}, Pallavi Parashar², James Closmann¹

¹University of Colorado School of Dental Medicine, 13065 E 17th Avenue, Aurora, CO 80045

²Private Practice

ABSTRACT

Aim: Present case of Botryoid Odontogenic Cyst

Presentation of Case: A 51 year old African-american female was referred for an anterior mandibular radiolucency.

Discussion and Conclusion: The examination findings and differential diagnosis are discussed along with treatment and follow up recommendations. A review of the histopathology for this interesting lesion is presented with histomicrographs.

Keywords: Botryoid Odontogenic Cyst, Lateral Periodontal Cyst, Oral Pathology, Oral Surgery

1. INTRODUCTION

Botryoid odontogenic cyst (BOC), the polycystic variant of the lateral periodontal cyst (LPC), was first described by Weathers and Waldron in 1973. These authors selected the descriptive name based on the grape-like arrangement of the cysts and their likely odontogenic origin [1]. LPC and BOC are developmental lesions which undergo sudden and rapid expansion in adult patients.

BOC is an aggressive jaw cyst that can present radiographically as unifocal or multifocal [2, 3, 4, 5]. The histologic appearance of LPC is unicystic, whereas BOC, by definition, is always polycystic [1, 3, 5].

Both LPC and BOC most commonly present in the anterior mandible in the premolar/cuspid region, but rarely some lesions occur in the maxilla in the cuspid region [3, 5, 6, 7]. It may present with expansion, paresthesia, or pain [2, 4, 6]. The incidence of clinical symptoms in BOC approaches 64% of patients [5]. There are reports of local destruction with perforation of cortical bone [3]. Tooth root divergence may noted on radiographic exam [4].

Gender predilection has not yet been established with studies reporting either slight male or slight female predilections [3, 5]. Some report an age predilection of 3rd - 7th decade, while others report a narrower range covering the 5th and 6th decades [2, 3, 6]

2. PRESENTATION OF CASE

An otherwise healthy 51 year old African American female presented on referral from her general dentist to the oral and maxillofacial surgery service for evaluation and treatment of an anterior mandibular radiolucent lesion between teeth #27 and 28 (Figures 1, 2, 3). The lesion was approximately 1cm x0.8cm, asymptomatic and discovered on routine radiographic examination.

* Tel. 801.336.8793

E-mail address: darintjohnston@icloud.com

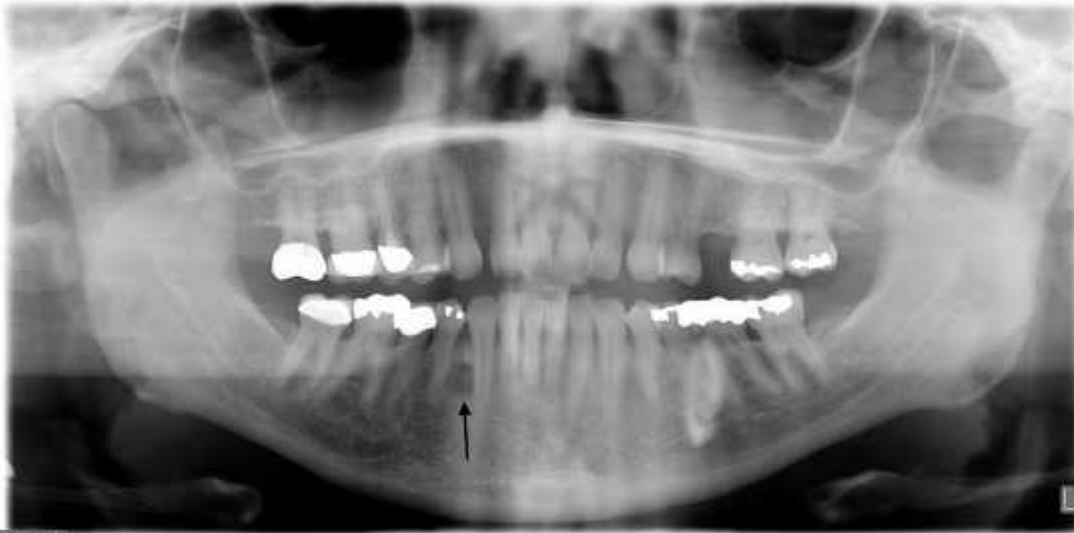

Figure 1. Orthopantomograph showing a well-circumscribed radiolucent area between #27-28 (arrow).

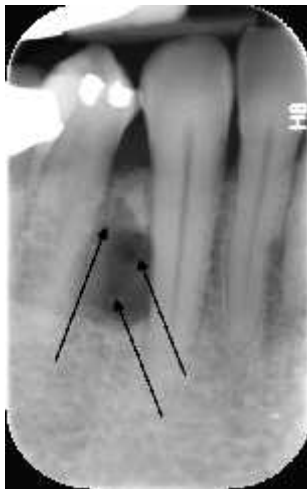

Figure2.Periapical radiograph showing multilocular appearance of radiolucent lesion (arrows).

On closer inspection of her panoramic and periapical radiographs (figures 1-2) the lesion was noted to have several loculations and was causing slight divergence of the tooth roots. Her intraoral exam revealed no bony expansion or tenderness over the area in question and teeth #27 and 28 tested vital. Her head and neck exam was unremarkable and the patient was a nonsmoker and did not consume any alcohol. A presumptive deferential diagnosis was made and included: Odontogenic Keratocyst, Ameloblastoma, Central giant cell granuloma, lateral periodontal cyst, BOC, and glandular odontogenic cyst.

After initial consultation and informed consent counseling with the patient the decision to perform a biopsy was made. Under local anesthetic a full thickness mucoperiosteal flap was made to expose the bone in the area of teeth 27 and 28. A bony window was then made using hand instrumentation to encounter the lesion. A somewhat dense soft tissue mass (figure 3) was then encountered and removed with curettes and submitted for histological examination. The wound was then closed in the usual fashion.

2.1 Histopathologic Findings

Histological evaluation of the biopsied specimen revealed multiple cavities lined by epithelium in a background of non inflamed fibrous connective tissue on low power. (Figure 4) On higher magnification these individual cystic cavities were lined by flattened squamous epithelium with focal nodular thickenings. These focal nodular excrescences exhibit a swirling pattern of the cells. (Figure 5)

2.2 Diagnosis

Botryoid Odontogenic Cyst

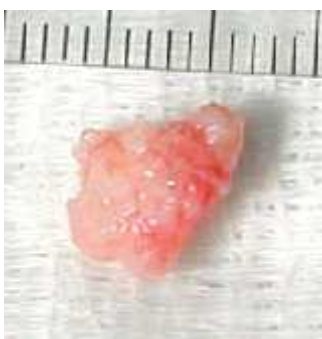

Figure 3. Excised lesion showing lobular surface. 8mm x 10mm.

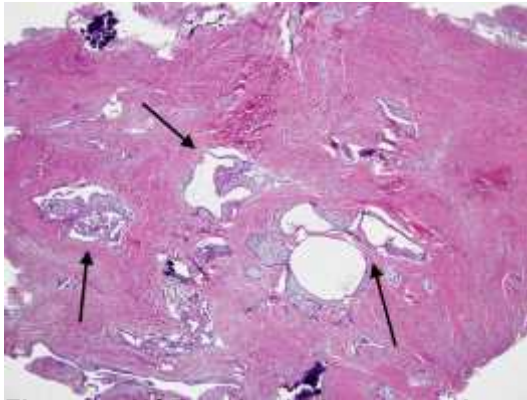


Figure 4. H&E stained biopsy specimen at 40x showing multiple epithelium lined cavities.

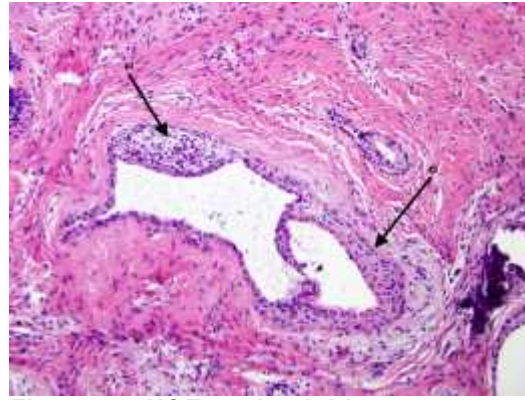


Figure 5. H&E stained biopsy at 400x showing epithelial plaques.

2.3 Treatment

Due to the elevated recurrence rate for botryoid odontogenic cysts the decision was made to perform a more thorough curettage of the bony cavity that contained the cyst to decrease the chance for recurrence. Under intravenous sedation the bony cavity was thoroughly curetted without complication and the patient went on to heal uneventfully. She was instructed to have yearly follow up examinations with radiographs at her recall exams as per the usual protocol with particular attention to the area.

3. DISCUSSION

The average size of the LPC is 0.3-0.8cm [4]. The BOC average size is larger at 0.5-1.8cm, with some lesions reaching sizes greater than 4cm [3, 4]. In Greer and Johnson's report of 10 cases all 8 BOC lesions less than 1.8cm appeared unilocular, indicating the size of the lesion may influence whether it presents radiographically unilocular or multilocular. However, the largest lesion in this series measured 4.5cm and was unilocular [1]. The lesion in this case is unusual because it was radiographically multilocular despite its relatively small size of 1cm

Siponen considered treatment for LPC and BOC best accomplished with complete enucleation and curettage [4]. Stoelinga recommends an initial incisional biopsy, followed by a possible marginal or sectional resection [2]. Mendez conceded that conservative treatment combined with Carnoy solution may reduce recurrence rate [5].

Without the benefit of hindsight the original reporting authors recognized the theoretical possibility of recurrence, due to cystic degeneration of remnant epithelial plaques, yet concluded recurrence was not likely [1]. However, current literature indicates recurrence is a major concern, especially when more conservative treatment was utilized [2].

Of significant importance to surgical planning are two trends that may indicate increased risk for recurrence. Mendez et al, summarizing 67 BOC cases from 1973-2005, recognized 9 of the 11 recurrences were initially radiographically multilocular, whereas only 5 of the 21 recurrences were multilocular. Additionally, Mendez et al, summarizing the 10 cases reported in 1988 by Greer et al, identified that among recurrences the mean size of initial lesions was 3cm compared to less than 1cm for non-recurrent cases [5].

The median time of recurrence appears to lie somewhere between 4 and 13 years [5]. Therefore, long-term follow-up is required.

4. CONCLUSION

BOC is by definition polycystic when evaluated histologically. However, the radiographic presentation is usually unilocular, identical to the LPC. This apparent incongruence could potentially lead to under treatment—and subsequent recurrence(s)—if a unilocular lesion isn't accurately diagnosed histologically prior to definitive treatment. Furthermore, the histological diagnosis is not straightforward. Caution should be exercised during the diagnosis, treatment, and follow-up period.

COMPETING INTERESTS

Authors have declared that no competing interests exist.”

CONSENT (WHERE EVER APPLICABLE)

All authors declare that ‘written informed consent was obtained from the patient (or other approved parties) for publication of this case report and accompanying images. A copy of the written consent is available for review by the Editorial office/Chief Editor/Editorial Board members of this journal.

REFERENCES

1. Weathers, D. R., & Waldron, C. A. (1973). Unusual multilocular cysts of the jaws (botryoidodontogenic cysts). *Oral Surgery, Oral Medicine, Oral Pathology*, 36(2), 235–241. doi:10.1016/0030-4220(73)90244-2
2. Stoelinga, P. J. W. (2012). The management of aggressive cysts of the jaws. *Journal of Maxillofacial and Oral Surgery*, 11(1), 2–12. doi:10.1007/s12663-012-0347-9
3. Greer, R. O., & Johnson, M. (1988). Botryoidodontogenic cyst: Clinicopathologic analysis of ten cases with three recurrences. *Journal of Oral and Maxillofacial Surgery*, 46(7), 574–579. doi:10.1016/0278-2391(88)90147-4
4. Siponen, M., Neville, B. W., Damm, D. D., & Allen, C. M. (2011). Multifocal lateral periodontal cysts: a report of 4 cases and review of the literature. *Oral Surgery, Oral Medicine, Oral Pathology, Oral Radiology, and Endodontics*, 111(2), 225–33. doi:10.1016/j.tripleo.2010.09.072
5. Méndez, P., Junquera, L., Gallego, L., & Baladrón, J. (2007). Botryoidodontogenic cyst: clinical and pathological analysis in relation to recurrence. *Medicina Oral, Patología Oral Y Cirugía Bucal*, 12(8), E594–8.
6. Kaugars, G. E. (1986). Botryoidodontogenic cyst. *Oral Surgery, Oral Medicine, and Oral Pathology*, 62(5), 555–9.
7. Uçok, O., Yaman, Z., Günhan, O., Uçok, C., Doğan, N., & Baykul, T. (2005). Botryoidodontogenic cyst: report of a case with extensive epithelial proliferation. *International Journal of Oral and Maxillofacial Surgery*, 34(6), 693–5. doi:10.1016/j.ijom.2005.01.005