Spinal neurobrucellosis is an unusual cause of nontraumatic paraplegia in Zaria, Northern Nigeria: A report of 3 cases and review of current literature.

OR Obiako, SA Abubakar, JA Kehinde, EU Iwuozo, AU Hamidu[1].
Neurology Unit, Department of Medicine, Radiology[1], Ahmadu Bello University Teaching Hospital (ABUTH) Zaria
Correspondence: Dr OR Obiako,
Email- orobiako87@gmail.com

.

ABSTRACT (ARIAL, BOLD, 11 FONT, LEFT ALIGNED, CAPS)

Introduction: Brucellosis is a zoonotic febrile infection common among farmers or herdsmen who come into contact with animals or animal products. Neurological complications are uncommon, but when they occur can be confused with other neurological diseases, particularly those due to tuberculosis (TB).

Aim: This report is intended to remind health workers and people living in Brucella endemic communities that spinal neurobrucellosis can mimic Potts' disease as the cause of nontraumatic paraparesis or paraplegia.

Study design: longitudinal case series

Methodology: We report the cases of three patients who presented with paraplegia following months of constitutional symptoms of fever, headache, malaise and weight loss. All were exposed to cows, goats and sheep. One patient had received antituberculous therapy for 18 months with minimal recovery. Serology and neuroimaging were used to confirm the diagnosis.

Results: All patients recovered within 6 to 12 weeks of rifampicin, doxycycline, trimethoprim-sulfamethoxazole or streptomycin, but with residual paraparesis.

Conclusion: spinal neurobrucellosis can be confused with Pott's disease (TB of the

* Tel.: +234 7064 836233.
E-mail address: orobiako87@gmail.com.

spine) with consequent poor treatment outcome.

Keywords: spinal neurobrucellosis, zoonosis, paraplegia, serology, neuroimaging

Introduction

Brucellosis, also called Malta fever or Mediterranean fever (it was first described in Malta in the Mediterranean region) is caused by intracellular gram-negative bacteria of the genus Brucella. It is the most common zoonosis in the world, accounting for the annual occurrence of more than 500,000 cases [1]. All *Brucella* infections are caused by direct or indirect exposure to animals or animal products (e.g., milk, milk products and raw meat), although possibility of aerosolized person to person transmission exists. Human disease is caused by any of four species: *Brucella melitensis* (affecting goats, sheep, camel); *Brucella abortus* (cattle); *Brucella suis* (pigs, hogs) and *Brucella canis* (dog) [2]. Symptoms are variable and non specific because any organ or system in the human body can be affected, but the main features are remittent fever which can be intermittent, relapsing and undulant in nature. Others are somatic symptoms of headache, body pains, night sweats, anorexia, fatigue, malaise, weight loss, and depression [2].

Neurobrucellosis is a rare complication of Brucellosis [3, 4], in which any part of the neuraxis may be involved. Chronic spinal localization is a rare but well documented event, and spinal cord compression can simulate Pott's disease [3, 5]. Sometimes the patients receive antituberculous drugs with some recovery [3].

In endemic area we advise screening for TB, brucellosis, typhoid and paratyphoid infections. This paper presents some difficulties in the diagnosis and management of neurobrucellosis.

* Tel.: +234 7064 836233.
E-mail address: orobiako87@gmail.com.

42
43
44

45

46 **Case Reports**

47 1. A.R, a 15 year old Fulani milkmaid, who also ingested unpasteurized milk
48 regularly, developed intermittent fever of 5-7days intervals, profuse night sweats,
49 anorexia, fatigue, malaise and hearing loss for 8 weeks. At the 7th week she
50 developed insidious non- radiating band-like, low back pain, and progressive lower
51 limb weakness culminating in paraplegia and double incontinence at the 8th week.
52 She therefore became bedbound leading to development of multiple gluteal sores
53 and anterior right thigh abscess. At 10th week, she presented to our centre when
54 she developed severe tetanus of one day duration.
55 On examination, she was chronically ill-looking, asthenic, conscious, but febrile
56 (temperature 38.7 ^{0}C), diaphoretic and pale. She had multiple gluteal and
57 trochanteric ulcers discharging cheesy/putrid materials; and episodic titanic spasms
58 with locked-jaw, trismus, opisthotonus and rigidity. She also had spastic paraplegia,
59 bilateral extensor plantar reflexes, and sensory loss at level T12, but no obvious
60 vertebral deformity or gibbus. She was incontinent of both faeces and urine, and
61 had a diaper on. X-rays of the spine, pelvis and hips did not reveal abnormalities.
62 She was treated with intravenous human tetanus immunoglobulins 10,000
63 international units (I.U) stat after a test dose, metronidazole infusions 500 mg 8
64 hourly, and intermittent diazepam 20-40 mg in 5% dextrose saline 8-12 hours until
65 spasm free. She received 3 pints of packed cells blood transfusion, and recovered
66 from tetanus within 2 weeks of admission. She was also investigated for brucellosis,
67 found positive and was treated with antibiotics. She recovered and was discharged

* Tel.: +234 7064 836233.
E-mail address: orobiako87@gmail.com.

home with residual paraparesis at 12th week of admission. The results of laboratory investigations, drug regimen and outcome of treatment are summarized in table 1.

2. J.N, a 13 year old student developed intermittent fever of 5-7 days intervals, headache, neck pain and loss of consciousness for 2 weeks. He was treated for possible pyogenic meningitis with parenteral ceftriaxole at a private hospital where he first presented; and regained consciousness after 10 days. However, the fever continued and he developed paraplegia, urinary retention and incontinence within 4 weeks of illness. There was no history of antecedent diarrhea, upper respiratory tract infection, or recent vaccination. Eight weeks later, he developed a sinus above the gluteal cleft which discharged a cheesy material. He worked in his father's animal farm which consisted of pigs, goats and sheep, but did not ingest unpasteurized milk.

On examination, he was fully conscious, febrile (temperature 37.6^0 C), pale and dehydrated. He also had nuchal rigidity with positive Brudzinski and Kernig's signs, flaccid paraplegia, and loss of sensation below the knee joints (L 4 and below). There was a sinus which was discharging cheesy material from a slit-like opening above the gluteal cleft on the midline. He was incontinent of urine, but not of faeces, and there was no obvious vertebral deformity or no gibbus.

He was investigated for brucellosis, found positive and treated with antibiotics. Constitutional symptoms of brucellosis resolved within 2 weeks of treatment as shown by the pattern of fever at presentation and 15 days after (in figures I and II respectively), but his neurologic deficit persisted. He was instructed to continue his drug regimen for 16- 24 weeks but was discharged on request with residual

* Tel.: +234 7064 836233.
E-mail address: orobiako87@gmail.com.

91 paraparesis at 12th week of therapy. He was lost to follow-up. The results of his
92 laboratory tests, drug regimen and outcome of treatment are summarized in table 1.
93 3. M.D, a 56 year old man who worked as a veterinary health extension worker in
94 Kaduna State Ministry of Agriculture and Animal resources presented with 2 years
95 history of headache, anorexia, weight loss, fatigue and progressive lower limb
96 weakness resulting in paraplegia and urinary incontinence. He had completed 18
97 months course of antituberculous therapy for suspected Pott's disease with minimal
98 improvement. His daily routine of more than two decades was vaccination of herds
99 of cows, sheep, goats and pigs. He never ingested unpasteurized milk. On
100 examination, he was fully conscious, pale, afebrile and mildly wasted. He had
101 spastic paraplegia, bilateral extensor plantar reflexes, sensory loss at level T10, and
102 urinary incontinence. There were multiple vertebral deformities and gibbus.
103 He was put on anti-brucella therapy after investigations, and within 12 weeks
104 muscle power in his lower limbs improved from 0/5 to 3/5. He was instructed to
105 continue his drug regimen for 16-24 weeks, but was also lost to follow-up due to
106 loss of job (income) and spouse. The details of his laboratory results, drug regimen
107 and outcome of treatment are summarized in table 1.

108 **Discussion**

109 Northern Nigeria is indigenous to herdsmen and cultures engaged in animal
110 husbandry; and since the risk of brucellosis is proportional to the degree of contact
111 with Brucella-infected animals, their excreta, or their edible byproducts; the disease
112 is expected to be endemic in our environment [5]. Prolonged contact with animals
113 and their edible byproducts were main risk factors for the disease in our patients.

* Tel.: +234 7064 836233.
E-mail address: orobiako87@gmail.com.

Cases of acute uncomplicated brucellosis are not commonly reported in our hospitals, either because health workers are unfamiliar with the infection, or the similarities of its acute constitutional symptoms are confused with those of other tropical infectious diseases particularly malaria fever, typhoid fever and tuberculosis [6]. This may explain why all 3 patients were misdiagnosed at the peripheral hospitals where they first presented before they were referred to us because of the complications they developed.

In Nigeria it is common practice for primary physicians to put most nontraumatic paraparesis or paraplegic patients on empiric anti tuberculous therapy with variable outcome [5]. This is borne out of the belief that Pott's disease is the commonest cause of nontraumatic compressive myelopathy because of high prevalence of TB infection in the country [7]. This common management error must be discouraged.

Neurobrucellosis affecting the central (CNS) or peripheral nervous system (PNS) has been described in 3–5% of patients, with a variety of clinical manifestations and imaging abnormalities that mimic other neurologic diseases [3, 5]. Although our patients had similar constitutional symptoms and neurological signs, the patterns and extent of spinal cord damage were different. Acute and chronic spinal neurobrucellosis (myelopathy) may result from several mechanisms such as acute transverse myelitis, spinal cord infarction, adhesive arachnoiditis, compression from epidural abscess, brucella spondylitis, and/or vertebral erosion and collapse [8, 9]. Diagnostic confusion may occur with lumbar disc protrusion and tuberculous spondylitis [8]. Cervico-brachial plexopathies, and lumbo-sacral plexo-radiculopathies, mononeuritis multiplex and peripheral neuropathies have been described [7].In the first and second patients (case 1 and 2), paraplegia was due to

* Tel.: +234 7064 836233.
E-mail address: orobiako87@gmail.com.

138 inflammatory changes in the spinal cord (myelitis & demyelination of white matter),
139 and spinal cord and nerve roots (myelitis, demyelination of white matter &
140 polyradiculitis) respectively; in the third patient (case 3), osteospondylitic extraaxial
141 compression of the spinal cord (by granulomas or abscess formation) was probably
142 responsible. These lesions are said to result from direct or indirect immunological
143 processes involving cytotoxic T lymphocytes, microglia and humoral immune
144 activation leading. Therefore spinal neuroimaging may show normal architecture (if
145 lesion is early and mild), or abnormal enhancement (for inflammatory changes and
146 demyelinating lesions) [5].
147 An understanding of the behavior of the humoral immune system is important in the
148 diagnosis of brucellosis. The level of immunoglobulin M (IgM) antibodies begins to
149 rise at the end of the first week of infection, peaks at about one month, and will
150 remain elevated for years; even in the absence of active infection. IgA antibodies
151 are elaborated late but may also persist for years. On the other hand, IgG
152 antibodies begin to appear at approximately one month of infection, and begin to
153 disappear thereafter. Therefore, persistent elevation of IgG antibodies is an
154 indication of chronic active infection, or a relapse of the illness [10, 11]. In our
155 centre, we test the sera of our patients against the IgG antibodies of *B melitensis*
156 because this organism is the most common cause of human brucellosis globally.
157 Recovery of *Brucella* organisms from cultures of CSF or blood is usually very low in
158 neurobrucellosis because the organisms are chiefly intracellular in locations,
159 although the CSF may exhibit pleocytosis, hypoglycorrhachia, and elevation of
160 protein concentration. The CSF findings of this disease can thus mimic those of
161 other intracellular organisms such as mycobacteria, fungi and toxoplasma [12].

* Tel.: +234 7064 836233.
E-mail address: orobiako87@gmail.com.

162 In endemic areas, isolation of bacteria from serum or cerebrospinal fluid (CSF) is
163 the gold standard diagnostic method, but appropriate serological tests such as IgG
164 agglutination titers of >1:160 in CSF or >1:320 in serum can be diagnostic,
165 particularly if there are rising titers in serial testing [10]. Rapid diagnosis and
166 treatment often leads to prompt and complete recovery in acute infection, but
167 response to appropriate antibiotic is variable in chronic brucellosis [13]. Treatment
168 entails use of triple drugs selected from rifampicin, doxycycline, gentamicin,
169 streptomycin, trimethoprim-sulfamethoxazole and ciprofloxacin, usually for periods
170 of 6 weeks (streptomycin) and 3 months (for others). Standard treatment for adults
171 with acute spinal brucellosis comprises capsule doxycycline 100 mg BD and tablets
172 trimethoprim-sulphamethaxole 960 mg BD, or capsule rifampicin 600 mg for at least
173 12 weeks, combined during the first 3-4 weeks with IM streptomycin. Treatment is
174 prolonged for 18-24 weeks in chronic neurobrucellosis [13]. Clinical improvement as
175 well as improvement in CSF pleocytosis and fall in CSF and blood *Brucella* titers
176 should occur after appropriate treatment. Poor outcomes are associated with
177 complications such as raised intracranial pressure, stroke, endocarditis, intracranial
178 mycotic aneurysm and haemorrhage, and osteospondylitis with compressive
179 myelopathy or radiculopathy [3].
180 In conclusion, neurobrucellosis is a treatable disease with a favorable outcome, but
181 because acute symptoms are similar to many tropical fevers, the infection may be
182 misdiagnosed with dare consequences. Also, the presence of complications like
183 meningoencephalitis and myelopathy worsens the prognosis. Therefore the disease
184 will continue to be an important health problem in developing countries unless
185 certain steps are taken to reduce its incidence. The steps must include avoidance of

* Tel.: +234 7064 836233.
E-mail address: orobiako87@gmail.com.

unpasteurized dairy products, animal contact or improperly cooked meat; regulation of abattoirs; surveillance, culling and vaccination of herds of sheep, goats, cows and pigs.

References

1. Edwards C, Jawad AS. History of brucellosis. J R Soc Med 2006; **99 (2**):54

2. Young EJ. Human brucellosis. Rev Infect Dis 1983; **5 (5):** 821-842

3. Ceran N, Turkoglu R, Erdem I, Inan A, Engin D, Tireli H, et al. Neurobrucellosis: clinical, diagnostic, therapeutic features and outcome. Unusual clinical presentations in an endemic region. Braz J Infect Dis. 2011; **15 (1):** 52-59.

4. Obiako OR, Ogoina D, Danbauchi SS, Kwaifa SI, Chom ND, Nwokorie E. Neurobrucellosis- a case report and review of literature. Niger J Clin Pract 2010; **13 (3):** 10-15

5. Al-Sous MW, Bohlega S, Al-Kawi MZ, Alwatban J, McLean DR. Neurobrucellosis: clinical and neuroimaging correlation. Am J Neuroradiol 2004; **25**: 395-401.

6. Badiaga S, Imbert G, La Scola B. Imported brucellosis associated with plasmodium falciparum malaria in a traveler returning from the tropics. J Travel Med 2005; **12 (5):** 282-284.

7. Nigeria Tuberculosis Fact Sheet. United States Embassy in Nigeria. http://photos.state.gov/libraries/nigeria/487468/pdfs/JanuaryTuberculosisFactSheet.pdf. Accessed online 30/05/2013.

8. Bahemu Ka M, Shemena AR, Panyiotopoulis CP. Neurologic syndromes of brucellosis. J Neurol Neurosurg psychiatry. 1988; **51**:1017-1021.

9. Shakir RA, Al-Din AS, Araj GF, Lulu AR, Mousa AR, Saadah MA. Clinical categories of neurobrucellosis; a report on 19 cases. Brain 1987; **110**:213-223.

* Tel.: +234 7064 836233.
E-mail address: orobiako87@gmail.com.

210 10. Young EJ. Serologic diagnosis of human brucellosis: analysis of 214 cases by
211 agglutination tests and review of the literature. Rev Infect Dis 1991; **13 (3):** 359-372.
212 11. Araj GF, Kattar MM, Fattouh LG, Bajakian KO, Kobeissi SA. Evaluation of the
213 PANBIO Brucella IgG and IgM enzyme-linked immunosorbent assays for the
214 diagnosis of human brucellosis. Clin Diagn Lab Immunol 2005; **12 (11):** 1334-1335.
215 12. Bouza E, Garcia de la Torre M, Parras F. Brucellar meningitis. Rev Infect Dis
216 1987; **9 (4):** 810-822.
217 13. Alp E, Doganay M. Current therapeutic strategy in spinal brucellosis. Int J Infect
218 Dis 2008; **12 (6):** 573-577
219
220
221
222 Table i. Summary of Laboratory test results, drug regimen, duration of therapy and
223 outcome.
224

* Tel.: +234 7064 836233.
E-mail address: orobiako87@gmail.com.

INVESTIGATIONS	CASE 1	CASE 2	CASE 3
HIV I & II	NEGATIVE	NEGATIVE	NEGATIVE
MANTOUX SKIN REACTION	< 5 MM (NEGATIVE)	< 5 MM (NEGATIVE)	< 5 MM (NEGATIVE)
CHEST X RAY	NORMAL	NORMAL	NORMAL
LEUCOCYTES (NORMAL 2-11X10 ^{9}/L)	LYMPHOCYTIC PLEOCYTOSIS	LYMPHOCYTIC PLEOCYTOSIS	NORMAL
HEMOGLOBIN (NORMAL 11- 16 G/DL)	6.9 (SEVERE ANEMIA)	10.2 (MILD ANEMIA)	14.0 (NORMAL)
INITIAL BRUCELLA ABORTUS IGG SEROLOGY	1/320	1/320	1/320
BRUCELLA ABORTUS IGG SEROLOGY 4 & 12 WEEKS RESPECTIVELY	1/16, <1/16	1/16, < 1/16	1/64, 1/16
CSF ANALYSIS *RELATIVE TO RANDOM	PLEOCYTOSIS, MARKEDLY ELEVATED PROTEIN, LYMPHOCYTOSIS, *HYPOGLYCORRHACHIA		LUMBAR PUNCTURE WAS CONSTRAINED

* Tel.: +234 7064 836233.
E-mail address: orobiako87@gmail.com.

BLOOD SUGAR			BY VERTEBRAL SPINE DEFORMITIES
CSF CULTURE	NEGATIVE	NEGATIVE	NOT DONE
HISTOPATHOLOGY OF CHEESY MATERIAL	NON CASEATING GRANULOMA	NON CASEATING GRANULOMA	NOT APPLICABLE
SPINAL MRI	FIGURE III(AREA OF HYPER-INTENSITY ON A SEGMENT OF SPINAL CORD)	FIGURE IV(AREAS OF HYPER-INTENSITIES ON MANY SEGMENTS OF SPINAL CORD & SPINAL NERVE ROOTS)	NOT DONE
SPINE VERTEBRAL X RAY	NORMAL	NORMAL	DESTRUCTION OF INTERVERTEBRAL DISCS AND VERTEBRAL BONES T12, L1, L2
DIAGNOSIS	TRANSVERSE	TRANSVERSE	OSTEOSPONDYLITIC

* Tel.: +234 7064 836233.
E-mail address: orobiako87@gmail.com.

	MYELITIS	MYELITIS AND POLYRADICULITIS	EXTRAAXIAL COMPRESSIVE MYELOPATHY
DRUGS AND DURATION OF THERAPY	12 WEEKS OF CAPS RIFAMPICIN 450 MG DAILY, DOXYCYCLINE 100MG BD AND TABS TRIMETHOPRIM-SULPHAMETHAXOLE 960 MG BD. TO CONTINUE REGIMEN FOR 16 WEEKS	INTRAMUSCULAR STREPTOMYCIN 750 MG DAILY FOR 4 WEEKS, CAPS RIFAMPICIN 450 MG DAILY FOR 12 WEEKS, AND CAPS DOXYCYCLINE 100 MG BD FOR 12 WEEKS. TO CONTINUE REGIMEN FOR 16-24 WEEKS	INTRAMUSCULAR STREPTOMYCIN 1 GRAM DAILY FOR 12 WEEKS, CAPS RIFAMPICIN 600 MG DAILY FOR 24 WEEKS, AND CAPS DOXYCYCLINE 100 MG BD FOR 24 WEEKS.
OUTCOME	DISCHARGED HOME ON WALKING FRAME (LOWER LIMBS MUSCLE POWER	DISCHARGED HOME ON WHEELCHAIR (LOWER LIMBS	DISCHARGED HOME ON WHEELCHAIR (LOWER LIMBS

* Tel.: +234 7064 836233.
E-mail address: orobiako87@gmail.com.

	4/5) AT 12 WEEKS	MUSCLE POWER 3/5) AT 12 WEEKS	MUSCLE POWER 3/5) AT 12 WEEKS

225

* Tel.: +234 7064 836233.
E-mail address: orobiako87@gmail.com.

TEMPERATURE CHART

NAME [illegible] WARD FMW

LEDGER NO. 80 | 77 | 78

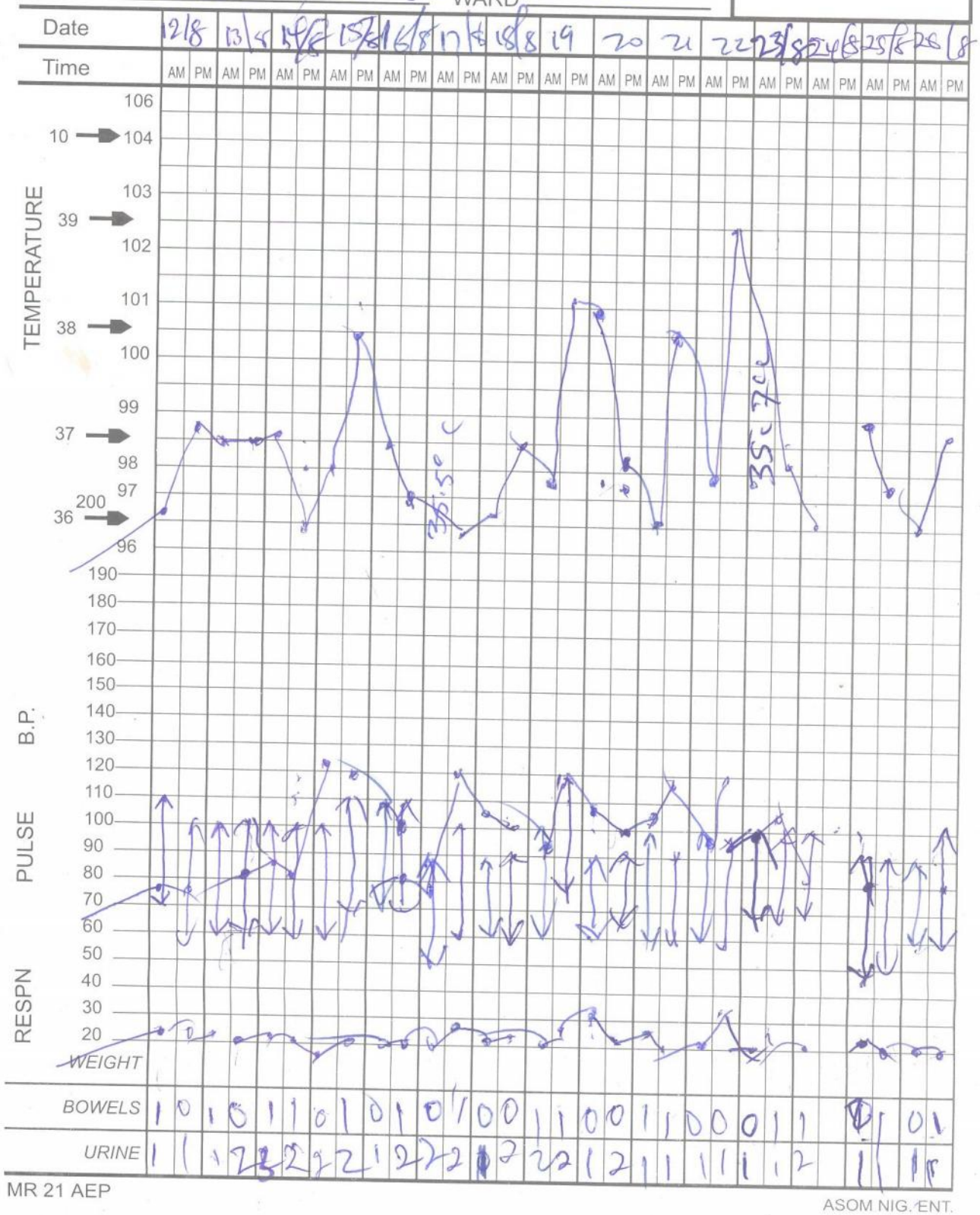

MR 21 AEP

ASOM NIG. ENT.

Figure 1. Undulant and intermittent temperature pattern before treatment (case 2)

* Tel.: +234 7064 836233.
E-mail address: orobiako87@gmail.com.

A.B.U HOSPITAL SHEET NO. 4

Unit No.		
30	97	78
LEDGER NO.		

TEMPERATURE CHART

NAME _____ WARD Fmw

Date	27/8	28/8	29/8	30/8	31/8	1/9	2/9	3/9	4/9	5/9	6/9	7/9	8/9	X	9
Time	AM PM	AM PM	AM PM	AM PM	AM PM	AM PM	AM PM	AM PM	AM PM	AM PM	AM PM	AM PM	AM PM	AM PM	AM PM

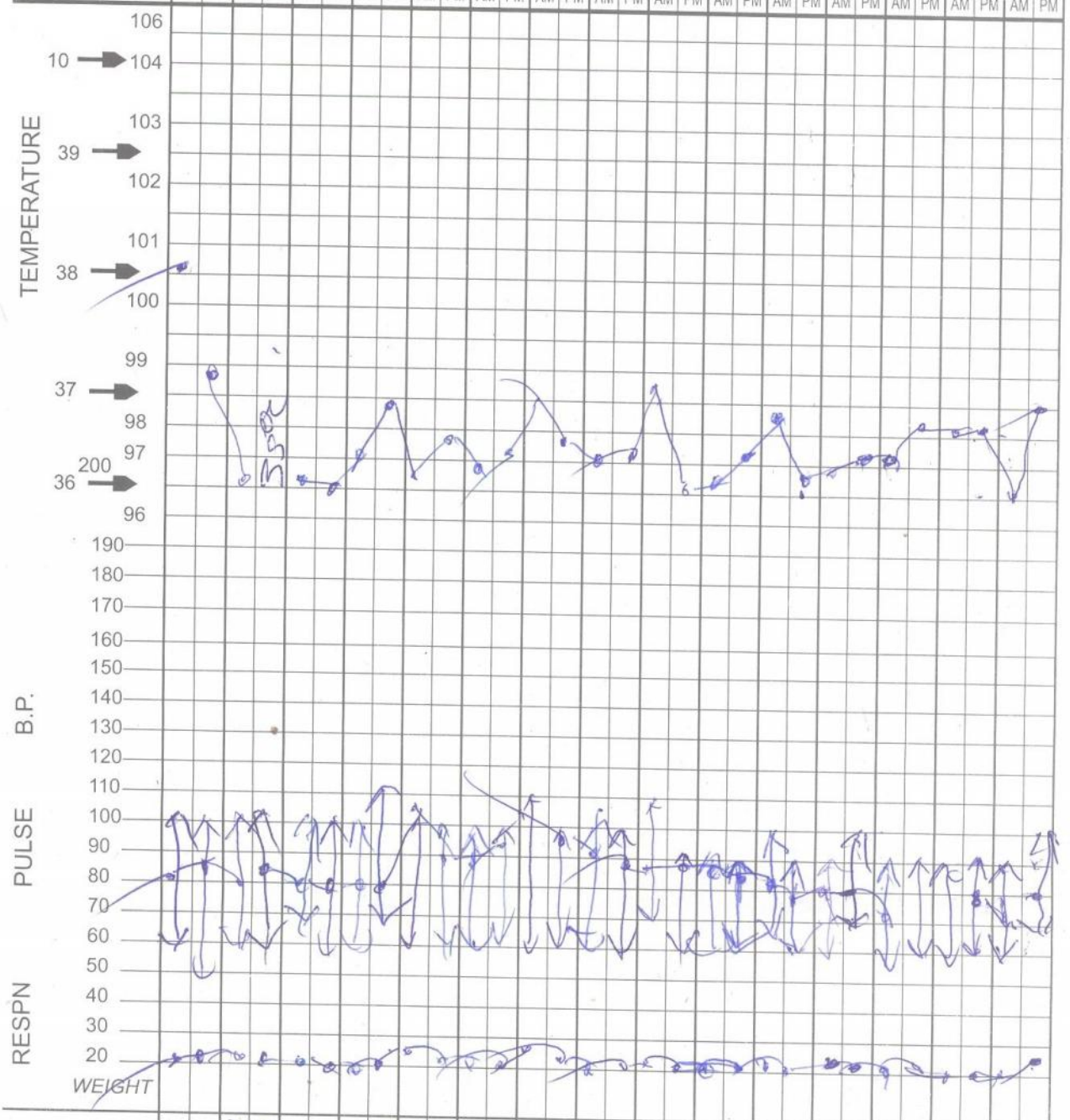

MR 21 AEP

ASOM NIG. ENT.

Figure 2. Normal temperature pattern after 15 days of treatment (case 2)

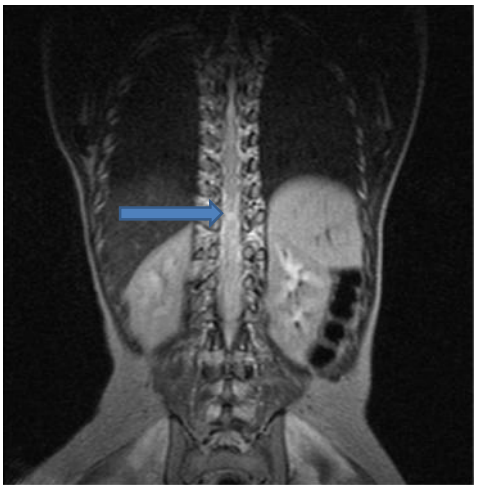

Figure 3. Coronal view of T2 weighted spinal MRI showing area of hyperintensity on a segment of the cord.

* Tel.: +234 7064 836233.
E-mail address: orobiako87@gmail.com.

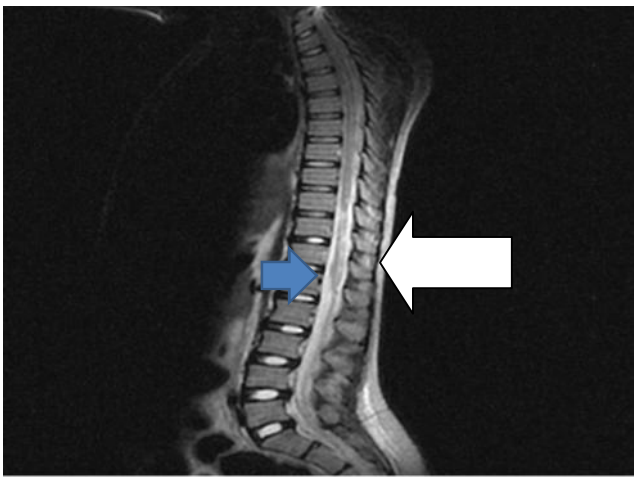

Figure 4. Sagittal view of T2 weighted spinal MRI showing areas of hyper intensities on many segments of the spinal cord and spinal nerve roots

* Tel.: +234 7064 836233.
E-mail address: orobiako87@gmail.com.