

# **Sarcomatoid Carcinoma (Carcinosarcoma) of the Prostate Gland: A Review of the Literature**

## **Abstract**

### **Background**

Adenocarcinomas of the prostate are extremely commonly encountered globally but other uncommon variants of carcinoma of the prostate are sporadically encountered including primary sarcomatoid carcinoma of the prostate (PSCP).

### **Aims**

To review the literature of PSCP

### **Methods**

Various internet search engines were searched for literature on PSCP

### **Literature Review**

About 100 cases of PSCP have so far been reported. PSCP may develop de novo or may emanate following hormonal treatment or radiotherapy for adenocarcinoma of prostate; PSCP may present with LUTS, haematuria, perineal/back pain. Histology of prostate biopsy tends to show a biphasic tumour which has an adenocarcinoma component as well as a second component which is a clearly recognizable type of sarcoma component which could be angiosarcoma, chondrosarcoma, leiomyosarcoma, osteosarcoma or rhabdomyosarcoma. With regard to immunohistochemistry Immunohistochemistry, the epithelial component of sarcomatoid carcinoma of prostate stains positively for cytokeratin and PAP, and negatively for PSA; the sarcoma component stains negatively for PSA, EMA and keratin. There is no consensus opinion on treatment. TURP has been performed for lower urinary tract obstruction symptoms and urinary retention, radical prostatectomy, pelvic exenteration, and chemotherapy are some of the treatments employed. A number of cases of PSCP had presented at advanced stages of the disease. PSCP is aggressive with poor prognosis; however, early aggressive surgery in some cases had resulted in survival.

### **Conclusions**

A multi-centre trial is required to determine the best treatment option for PSCP.

Perhaps patients with progressing prostate cancer following radiotherapy of castrate resistant prostate cancer should have repeat prostate biopsies to determine if they have developed dedifferentiation into PSCP or other variants of prostate cancer and to try cases of PSCP on chemotherapy as a trial.

**Key Words:** Sarcomatoid carcinoma of prostate; carcinosarcoma; immunohistochemistry; cytokeratin; PAP; EMA; PSA

## Introduction

Sarcomatoid carcinoma (carcinosarcoma) of the prostate is a rare tumour which can occur, de novo or following hormonal treatment or radiotherapy. It may be that lots of cases of PSCP are not detected and reported because many patients with castrate resistant carcinoma of prostate and patients with progressive carcinoma of prostate despite having had radiotherapy do not undergo repeat prostate biopsies to further assess the carcinomas and thus missing dedifferentiation of adenocarcinoma into other variants of prostate cancer. The ensuing review of the literature on sarcomatoid carcinoma (carcinosarcoma) of the prostate gland is divided into two parts: (A) overview and (B) discussions and narrations from some reported cases.

**Aim:** To review the literature relating to primary sarcomatoid carcinoma (carcinosarcoma) of the prostate gland.

**Methods:** Various internet data bases were searched including: Google, Google Scholar; PUB Med, Medline, and Educus. The search words used included sarcomatoid carcinoma of prostate; carcinosarcoma of prostate. Information obtained from 24 references was used for the literature **review**.

## Literature Review

### (A)

#### General Comment

- Sarcomatoid variant of carcinoma of the prostate gland is an uncommon malignancy and about 100 cases of the disease have so far been reported.

#### Other terminologies

- Other terminologies have been used for sarcomatoid variant carcinoma of the prostate and these include: sarcomatoid carcinoma, metaplastic carcinoma, spindle-cell carcinoma, and malignant mixed mesodermal tumour [1]

#### Aetiology

- Postulates relating to the aetiology of sarcomatoid carcinoma of the prostate gland include: it could either be representative of sarcomatoid transformation of prior adenocarcinoma of the prostate or it could be

96 related to previous radiotherapy treatment or to previous hormonal  
97 therapy. [1]

98

99 Presentation

100 Patients with sarcomatoid carcinoma of the prostate may present with:

- 101 • Lower urinary tract storage symptoms (frequency, urgency, urge  
102 incontinence) and voiding symptoms (poor stream, hesitancy,  
103 incomplete emptying of bladder) [2]
- 104 • Inability to void with retention of urine [2]
- 105 • Rarely they may present with haematuria and perineal pain [2]
- 106 • There may be a history of previous radiotherapy to a prostatic  
107 carcinoma or hormonal therapy for prostatic carcinoma. [3]
- 108 • Clinical examination findings including digital rectal examination  
109 which may show an enlarged prostate which could feel benign,  
110 irregular, nodular, hard or feel like a mass protruding into the rectum

111 Laboratory tests

112 Full blood count, serum urea and electrolytes, liver function tests, coagulation  
113 screen, urinalysis and urine culture and sensitivity are some of the routine tests  
114 that are done as part of the screening assessment of patients with carcinoma of  
115 prostate. Serum prostate-specific antigen (PSA) tests are routinely carried out  
116 in the initial investigation and follow-up of patients following treatment for  
117 adenocarcinoma of prostate. With regard to serum PSA and sarcomatoid  
118 carcinoma of prostate is that a number of cases of sarcomatoid carcinomas of  
119 prostate are associated with low-levels of serum PSA therefore serum PSA  
120 would not be that useful in the follow-up assessment of the sarcomatous  
121 component of sarcomatoid carcinoma of the prostate gland even though it may  
122 be useful in assessing the progress of the adenocarcinoma component of the  
123 tumour. The clinical progress of the patient and thorough clinical assessment  
124 of the patient as well as various radiological investigations are on the other  
125 hand useful in the follow-up assessment of the patients.

126

127 Radiological Investigations

128 Ultra-sound scan of renal tract and pelvis

129 Ultra-sound scan of the renal tract, abdomen and pelvis are useful in the  
130 general initial assessment of the patient for the characteristics of the tumour  
131 and the relationship of the tumour to near-by organs and the size of the  
132 prostate gland. The ultra-sound scan is also useful for the detection and  
133 exclusion of hydronephrosis as well as metastatic lesions in the lymph nodes

134 and other organs in the abdomen and pelvis. Ultra-sound guided insertion of  
135 nephrostomy plus or minus insertion of ante-grade ureteric stent can also be  
136 performed in cases of ureteric obstruction.

## 137 Computed Tomography (CT) Scan

138 CT scan of abdomen, pelvis, and thorax is useful for the assessment of the  
139 prostate and assessing whether or not there are any metastatic lesions in the  
140 pelvis, abdomen and thorax and bone lesions can also be picked up. CT scan is  
141 useful for the TNM staging of the tumour.

142

## 143 Magnetic Resonance Imaging (MRI) Scan

144 MRI scan is very useful in assessing the characteristics of the prostate as well  
145 as the prostatic lesion and its relationship with nearby organs. MRI scan is also  
146 useful in detecting or excluding metastatic lesions in the abdomen, pelvis and  
147 thorax. MRI scan is also useful for the TNM staging of the tumour.

148

## 149 Positron Emission tomography (PET) scan

150 PET scan is useful in assessing for metastatic lesion anywhere in the body.

151

## 152 Isotope Bone Scan

153 Isotope bone scan is useful in assessing whether or not a patient has or does  
154 not have bone metastasis.

155

156 Trans-rectal ultra-sound scan guided prostate biopsies / TUR /prostatectomy  
157 specimens

158 Specimens of the prostate gland by means of trans-rectal ultra-sound guided  
159 biopsy, trans-urethral resection of prostate or prostatectomy are used for the  
160 histopathological examination which is used for the diagnosis of the tumor and  
161 for assessing the degree of differentiation and grading of the tumours.

## 162 Macroscopic features

163 • There is nothing specific in the appearance of the gross appearance of a  
164 biopsy specimen of the prostate gland or prostatectomy specimen that  
165 is distinctive or diagnostic of sarcomatoid carcinoma of the prostate.  
166 Histological examination is required to establish the diagnosis.

167 • However, the prostatectomy specimens may consist of firm, greyish  
168 white nodular masses with variegated haemorrhagic surfaces. [4]

169 Microscopic features

- 170       • Sarcomatoid carcinoma of prostate gland (carcinosarcoma of the  
171 prostate gland) is a biphasic tumour which has an adenocarcinoma  
172 component as well as a second component which is a clearly  
173 recognizable type of sarcoma component which could be  
174 angiosarcoma, chondrosarcoma, leiomyosarcoma, osteosarcoma or  
175 rhabdomyosarcoma. [1]
- 176       • A carcinoma of the prostate gland therefore is called sarcomatoid  
177 carcinoma of prostate (carcinosarcoma of prostate) if microscopic  
178 examination of a prostate biopsy specimen or prostatectomy specimen  
179 shows (a) features of adenocarcinoma of the prostate and any of the  
180 type of the aforementioned sarcomas.

181 Immunohistochemistry features

182 The epithelial component of sarcomatoid carcinoma of prostate stains

- 183       • Positively for cytokeratin and PAP [5]
- 184       • Negatively for PSA [5]

185 The sarcoma component of sarcomatoid carcinoma of prostate  
186 (carcinosarcoma) stains:

- 187       • Negatively for PSA, EMA and keratin [5]

188 Differential diagnosis

189 Some of the differential diagnoses of sarcomatoid carcinoma of the prostate  
190 include:

- 191       • Primary sarcoma of the prostate gland [1]
- 192       • Benign spindle cell proliferations of the prostate gland for example  
193 inflammatory myofibroblastic tumour (pseudosarcomatous  
194 fibromyxoid tumour) [1]
- 195       • Post-operative spindle cell nodule

196 It has been stated that the aforementioned conditions could be confused with  
197 the mesenchymal component of sarcomatoid carcinoma and that with regard to  
198 recurrent tumours, the mesenchymal component often overgrows the epithelial  
199 component and hence a pure sarcomatous pattern within the setting of  
200 pretreated adenocarcinoma of prostate should be diagnosed as sarcomatoid  
201 carcinoma. [1]

202

203

204 Treatment

- 205       • In view of the rarity of PSCP, there is no consensus on treatment. A  
 206       number of patients would under prostatectomy by means of the open  
 207       method of by trans-urethral resection and histological examination of  
 208       the specimen would confirm PSCP. In such situations adjuvant  
 209       treatment with radiotherapy and or chemotherapy could be given.  
 210       Nevertheless, it is worth noting that some cases of sarcomatoid  
 211       carcinoma transformation develop after the patients had previously  
 212       undergone radiotherapy for adenocarcinoma of prostate in view of this  
 213       it is unlikely that radiotherapy would be effective. About 55.5% of  
 214       cases of PSCP do not respond effectively to systemic chemotherapy.
- 215       • Aggressive surgical operation in the form of radical prostatectomy or  
 216       anterior exenteration or total pelvic exenteration would appear to be  
 217       the best approach with curative intent and this could be combined with  
 218       adjuvant therapy.
- 219       • In cases of advanced disease supportive therapy / palliative therapy  
 220       would be required. Patients with bilateral or unilateral obstruction of  
 221       the ureter would require nephrostomy plus or minus insertion of  
 222       ureteric stent(s); Some patients may require catheterization of the  
 223       urinary bladder by means of urethral catheterization or insertion of  
 224       urethral catheter; pain control and other supportive and support of the  
 225       patient and his family through a multi-disciplinary team approach  
 226       (Palliative care team, urologists, urology nurse specialist, oncologist,  
 227       General Practitioner, the district nurse and the social care team) may be  
 228       required to provide good delivery of care.
- 229       • Hormonal therapy would only be able to control the adenocarcinoma  
 230       component of the prostatic tumour but would be ineffective in treating  
 231       the sarcomatoid component of the tumour. Furthermore, considering  
 232       the fact that a number of cases of sarcomatoid carcinoma develop  
 233       following hormonal treatment for adenocarcinoma of the prostate,  
 234       hormonal treatment would not be expected to be effective treatment for  
 235       PSCP.

236

237 Outcome

- 238       • Hansel and Epstein [3] had stated that sarcomatoid carcinoma (carcino-  
 239       sarcoma) of the prostate gland is associated with an aggressive clinical  
 240       course and that the prognosis of which dismal irrespective of other  
 241       histological or clinical findings.

242 (A) Discussion and miscellaneous narrations from some reported cases

243 Hansel and Epstein [3] stated that sarcomatoid carcinoma of the prostate gland is a rare  
 244 variant of carcinoma of the prostate gland and apart from 1 previous study the morphological  
 245 features of sarcomatoid carcinoma of the prostate gland and outcome of the patients had only

been reported only in individual case reports and relatively small case series. Hansel and Epstein [3] examined specimens of the prostate gland which were obtained by means of trans-urethral resection, needle biopsy of prostate and radical prostatectomy from 42 patients who had been diagnosed as having sarcomatoid carcinoma of the prostate gland. Hansel and Epstein [3] stated that they were able to obtain clinical information on 32 patients. With regard to the results, Epstein and Hansel [3] reported the following:

- History of prior adenocarcinoma of prostate: Twenty one patients (66%) who constituted the majority of patients had a prior history of acinar adenocarcinoma of the prostate gland. The reported Gleason scores of the adenocarcinomas of the prostate of 14 patients whose clinical data were available to them were Gleason 6, 7 patients; Gleason 8, 4 patients; and Gleason 10, 3 patients. With regard to the remaining patients whose data were known, 11 of the patients had presented with de novo sarcomatoid carcinoma. The mean interval of time between the original diagnosis of acinar adenocarcinoma of prostate and the subsequent diagnosis of sarcomatoid carcinoma of prostate was 6.8 years and the ages had ranged between 6 months and 16 years.
- Concurrent adenocarcinoma of prostate: Most of the patients had a concurrent high-grade acinar carcinoma of prostate. Three patients had Gleason score 7; nine patients had Gleason score 8; ten patients had Gleason score 9; and ten patients had Gleason score 10. A sub-set of the patients had other types of concurrent tumours. Four patients had ductal adenocarcinoma of prostate, three patients had small cell carcinoma of prostate, three patients had squamous cell carcinoma of prostate, and three patients had other unusual pattern of carcinoma of the prostate gland. With regard to one of the patients, the diagnosis was made based upon the immunohistochemistry evidence of epithelial differentiation together with the history of prior adenocarcinoma of the prostate gland.
- Morphology of the sarcomatoid component of the tumour: The mean percentage of sarcomatoid-growth in the tumour was 65% and the percentage sarcomatoid-growth in the tumour had ranged between 5% and 99%. Fifty five percent of the tumours had bizarre atypia with giant cells. Ten of the cases (29%) had admixed heterologous elements which included 7 cases with osteosarcomatous elements, 5 cases with chondrosarcomatous elements, and two patients with rhabdomyosarcomatous elements.
- Immunohistochemistry: Out of the 12 cases in which immunohistochemistry was performed, 5 out of 7 cases exhibited focal positivity for cytokeratin, 1 case out of 1 was focally positive for Cam5.2, and 3 cases out of 6 cases were focally positive for prostatic acid phosphatase. The sarcomatoid component did not show any immunoreactivity for prostate-specific antigen in 8 cases.
- Prognosis: About half of all the patients had developed metastatic disease either at the time of presentation or later on. With regard to patients who had meaningful follow-



up, six out of seven had died within one year of the diagnosis of sarcomatoid carcinoma of prostate; twenty of the patients at the time of publication of the paper were alive with very short follow-up with a median follow-up of one year and a mean follow up of 2.3 years. Kaplan-Meier analysis of the above results had shown that the actuarial risk of death at 1 year after the diagnosis of sarcomatoid carcinoma of prostate was 20%. There was no correlation found between the survival of patients and morphological characteristics, before radiotherapy or hormonal therapy, or evidence of concurrent high-grade carcinoma of prostate.

- Sarcomatoid carcinoma of prostate does demonstrate diverse spindle and epithelial cell morphologies. The sarcomatoid component of the prostatic carcinoma quite often exhibits heterologous elements, and in one case, there was no evidence of epithelial component on examination of haematoxylin and eosin-stained sections of the tumour. The epithelial component of sarcomatoid carcinoma of prostate characteristically high-grade acinar adenocarcinoma, but other aggressive sub-types of tumour inclusive of ductal adenocarcinoma and small cell carcinoma may also be observed. Sarcomatoid carcinoma of the prostate is an aggressive form of carcinoma of the prostate gland, the prognosis of which dismal irrespective of other histological or clinical findings.

AçJkgöz et al. [2] reported a 54-year-old man who had been on alpha-blocker therapy for the preceding year who presented with a 6-months history of lower urinary tract symptoms which included nocturia (3-4 times per night), pollakiuria, poor urinary flow with a decrease in the stream of his urine. He had a digital rectal examination which revealed a grade 1 mildly enlarged benign feeling prostate gland. He had trans-rectal ultra-sound scan of prostate revealed a prostate volume of 40 cc and normal ultra-sound scan appearance. His serum PSA was 20.5 ng / ml but the rests of his laboratory tests including serum urea and electrolytes, ALP and urinalysis were normal. He then had trans-rectal ultra-sound guided biopsy of prostate and its histology was found to show benign prostatic biopsy. He then underwent trans-urethral resection of prostate (TURP) and histological examination of the specimen revealed Gleason 5 + 3 = 8 adenocarcinoma of prostate (see figure 1a). He then had CT scan of abdomen, pelvis, and thorax as well as isotope bone scan which were normal. He was scheduled to undergo radical prostatectomy but during the procedure sampling of his obturator lymph nodes was undertaken and frozen section histological examination had revealed adenocarcinoma in the right obturator lymph node therefore the procedure of radical prostatectomy was abandoned and he was put on total androgen blockade. His serum PSA was noted to have come down to 0.6 ng / ml at his 1 month follow-up and his total androgen blockade was continued. At 3 months following his abandoned operation he was readmitted with acute lower urinary tract symptoms and he had ultra-sound scan of renal tract and pelvis which showed left sided hydronephrosis and a 2 cm mass in the prostate. He therefore underwent cystoscopy and what was considered to have been complete resection of the prostatic lesion that had projected into the urinary bladder and histological examination of the specimen had shown poorly differentiated tumour cells and the tumour was therefore classified as an undifferentiated tumour and detection of adenocarcinoma in <1% focus (see



figure 1b). Immunohistochemistry did show to be negative for pancytokeratin. He was continued on his total androgen blockade. Four months pursuant to his latest operation he was admitted because of inability to void. His serum PSA then was 1.77 ng / ml and his serum urea and electrolytes were normal. He underwent cystoscopy which had revealed regrowth of prostatic tissue projecting into and almost completely filling his urinary bladder for which incomplete trans-urethral resection of the prostatic lesion was carried out. Histological examination of the specimen showed “sarcomatoid malignant tumour” (see figures 1c and 1d). Light microscopic examination of the specimen revealed high cellularity, spindle and pleomorphic cells with bizarre appearance, and atypical mitotic figures as well as necrosis. The tumour on immunohistochemical analysis revealed the following staining characteristics:

- Negatively stained with Cytokeratin (AE1/AE3)
- Positively stained for Vimentin (V9)
- Positively stained for SMA
- Negatively stained for Factor VIII
- Negatively stained for C-kit (CD117) but there was rare, weak, granular positive staining in the Golgi area.
- Negatively stained for Cd34

He had PET CT scan which had shown that he had multiple metastases in the liver, lung and thoraco-lumbar vertebrae. He was referred to the oncology department for radiotherapy and chemotherapy. He was alive at his 9 months follow-up. Açıkgöz et al. [2] stated that:

- Their patient was followed-up under maximum androgen blockade treatment to keep his serum PSA less than 0.2 ng / ml during the disease period. Nevertheless, the efficacy of hormonal therapy observed in adenocarcinoma of prostate could not be experienced on sarcomatoid variant, thus causing the presence of sarcomatoid component to be missed out in patients who are followed-up by successive serum PSA measurements under hormonal therapy.
- Sarcomatoid carcinoma of the prostate gland is one of the rarest malignant types of neoplasms and it has been well known for its aggressive clinical course.
- At the time of publication of their paper in 2013 around 100 cases of sarcomatoid carcinoma of the prostate had been reported in the literature according to [6]
- The most recent World Health Organization (WHO) classification did not distinguish clinically between carcinosarcoma and sarcomatoid carcinonoma as two distinct lesions, even though there appears to be cases that are characterized, with regard to pathological diagnoses, with differentiation of adenocarcinoma of the prostate gland into sarcomatoid carcinoma and some others that are characterized with primary

carcinosarcoma containing both epithelial and mesenchymal cells. The terminology “sarcomatoid carcinoma” is used for both of these lesions [7]

- Sarcomatoid carcinoma of the prostate gland pursues an insidious course and generally manifests with symptoms related to filling of the urinary bladder (nocturia, urinary urgency and so on) and / or symptoms related to voiding (dysuria, slow urinary stream, hesitancy, terminal dribbling, feeling of incomplete emptying of the urinary bladder in adult and elderly populations. Patients afflicted by sarcomatoid carcinoma of the prostate gland are rarely admitted with haematuria, perineal / rectal pain, or painful ejaculation. [8]

AçJkgöz et al. [2] concluded that:

- Sarcomatoid carcinoma is a malignant variant which is associated with diagnostic and treatment difficulties.
- Lack of experience in the subject of sarcomatoid carcinoma of the prostate is a hindrance to the standardization of modalities.
- It had been suggested by Hansel and Epstein [3] that surgical resection of the curative tumours, adjuvant chemotherapy, and / or radiotherapy, together with palliative attempts in patients with advanced staged disease, would constitute the general approach to the management of sarcomatoid carcinoma of the prostate gland.

In 1993, Lauwers et al. [9] stated that carcinosarcoma of the prostate gland is a biphasic which contain adenocarcinoma (ACA) and recognizable sarcomatous components. They also stated that carcinosarcoma of the prostate is a rare tumour and at the time of the report of their cases in 1993, only 12 cases of carcinosarcoma of the prostate gland had previously been reported. Lauwers et al. [9] reported 3 additional cases which had arisen between 4 and 6 years following the initial diagnosis of adenocarcinoma of prostate. Two of the patients had previously undergone prostatectomy, external beam radiotherapy to the pelvis, and hormonal manipulation. The third patient had previously undergone pelvic lymphadenectomy and 125I implants. Lauwers et al. [9] further stated that following the development of the sarcomatous component of the tumour, the first two patients were still alive with distant metastases and residual pelvic disease at 9 months and 17 months. The third patient died 7 months after the diagnosis of the sarcomatous component of the carcinoma. Lauwers et al. [9] additionally stated that histological examination had shown that adenocarcinoma of prostate was in all of the three cases, as well as neoplastic mesenchymal component of the tumours which appeared later. Foci of osteosarcomatous, chondrosarcomatous, and myosarcomatous differentiation were identified in two of the three cases. Lauwers et al. [9] stated the following:

- Based upon the chronological and histological evolution of the neoplasm, they were in favour of sarcomatoid transformation of the adenocarcinoma of prostate as the most likely histogenesis of carcinosarcoma of prostate gland.
- It would appear that radiotherapy and hormonal treatment may be important in the development of at least some of these tumours.

Adekoyejo Abiodun et al. [4] in Nigeria reported a 60-year-old man who presented with symptoms of bladder outlet obstruction and whose serum PSA at presentation was 0.94 ng / L. Upon clinical assessment a diagnosis of benign prostatic hypertrophy was made. He underwent prostatectomy. **The prostatectomy specimen consisted of two firm, greyish white nodular masses with variegated haemorrhagic surfaces.** Histological examination of the specimen revealed a biphasic tumour with a predominantly spindle cell component which had comprised 80% of the tumour, as well as clusters and nests of small undifferentiated cells. Nests of a well differentiated keratinizing squamous cell carcinoma were also identified in the tumour which was EMA positive on immunohistochemical examination. A few of the small undifferentiated cells and stromal cells on immunohistochemistry studies found to be positive for EMA, but they were negative for desmin. Approximately, 40% of cells in stained sections were found to be positive for Ki-67. A diagnosis of sarcomatoid carcinoma of prostate gland with a Gleason score of 10 was made. The case was reported at a time when there was no long-term follow-up. Abiodun et al. [4] stated that to their knowledge even though a few cases of sarcomatoid carcinoma of the prostate have been reported in the literature, there had not been any previously reported case of sarcomatoid carcinoma of the prostate from Nigeria hence their case was the first to be reported from Nigeria. In view of the fact that there was no history of previous radiotherapy or hormonal treatment for prostate cancer in this reported case, it would be argued that the histogenesis of this carcinoma would be de novo carcinoma.

Zizi-Sempetzoglou et al. [6] reported a 76-year-old Caucasian man who had undergone trans-urethral resection of prostate as treatment for bladder outlet obstruction. Histological examination of the specimen showed a tumour which had malignant epithelial and sarcomatoid elements. The malignant epithelial component of the tumour comprised of poorly differentiated adenocarcinoma Gleason 5 + 4 = 9/10 and the sarcomatous component comprised mainly of undifferentiated spindle cells. Immunohistochemistry studies on the sarcomatous component of the tumour revealed positive immunohistological expression for vimentin. Many cells were positively stained for cytokeration AE3 and myoD1 but all of the cells were negative for actin, desmin, and myogenin. A final diagnosis of sarcomatoid carcinoma of prostate was made. Zizi-Sempetzoglou et al. [6] stated that:

- The sarcomatoid component in sarcomatoid carcinoma of the prostate gland can vary between 5% and 99%.
- Even though sarcomatoid carcinoma of the prostate gland is a very aggressive tumour, and the patients to have poor prognosis, their patient was still alive one year after the diagnosis.

Diao et al. [10] reported a 62-year-old man with adenocarcinoma of the prostate (Gleason 5 + 4 = 9) who was treated by means of androgen blockade and radiotherapy in 2010. His serum PSA was noted to have risen 13 months after his treatment. He underwent trans-urethral

resection of prostate and histological examination of the resected prostate revealed concomitance of squamous cell carcinoma, sarcomatoid carcinoma and adenocarcinoma of prostate Gleason 5 + 5 = 10. With regard to immunohistochemistry studies of the tumour, Diao et al. [10] stated that the expression of epithelial markers E-cadherin and  $\beta$ -catenin were significantly down-regulated, on the other hand mesenchymal marker vimentin was up-regulated in both squamous cell carcinoma and sarcomatoid carcinoma components of the tumour. The expression of androgen receptor (AR) was down-regulated in the squamous cell carcinoma component of the tumour but it was up-regulated in the sarcomatoid carcinoma component of the tumour. From the 13<sup>th</sup> month to the time of death of the patient his serum PSA level increased rapidly to 400 ng / ml. Diao et al. [10] stated the following:

- The altered epithelial and mesenchymal markers and the heterogeneous androgen receptor expression in the relapsed tumour would indicate that the concurrence of unusual sub-types of tumour may emanate from the epithelial – to – mesenchymal transition and / or the differential function of the androgen receptor on the epithelial and stromal cells of the prostate gland.
- Their reported case would indicate concerns regarding anti-androgen regimen for carcinoma of the prostate gland.

Nazim et al. [11] reported a 64-year-old man who had presented with voiding problems and retention of urine. His initial serum PSA level was 9 ng / ml. He had had trans-urethral resection of prostate (TURP) elsewhere. Histological examination of the resected prostate had revealed adenocarcinoma of prostate (Gleason 4 + 5 = 9). He was adjudged to have had locally advanced carcinoma of prostate on clinical staging work-up. He was commenced on luteinizing hormone releasing hormone (LHRH) analogue. Two months pursuant to his initial TURP he failed to void again and urethral catheterization failed. He underwent another TURP and histopathological examination of the specimen had shown adenocarcinoma of the prostate with sarcomatoid variant. Within the subsequent six weeks his voiding symptoms had worsen and he also developed visible haematuria which resulted in retention of urine and obstructive uropathy. He had insertion of supra-pubic catheter and bilateral percutaneous nephrostomy for bilateral hydronephrosis. At that stage his serum PSA was 0.5 ng / ml. He also developed severe constipation and deep seated pain in the pelvis and perineum. On clinical examination at that stage, a stony hard mass was palpated in his supra-pubic region through which his supra-pubic catheter was coming out. Another hard mass was palpable in his perineum which had involved the bulb of his penis. He had a digital rectal examination which revealed a stony, hard, irregular mass which had totally occluded the lumen of the rectum. He had magnetic resonance imaging (MRI) scan which showed an abnormal heterogeneous signal intensity mass lesion in the pelvis which had shown peripheral post-contrast enhancement with central necrotic component which measured 13 cm x 11 cm x 14 cm in the antero-posterior (AP), transverse and cranio-caudal dimensions and it had extended down into the perineum where it measured 8.9 cm x 3.8 cm x 5.2 cm and was noted in this area to have involved the root of the penis. The mass had infiltrated superiorly into the urinary bladder and had completely filled the lumen of the urinary bladder. The mass had abutted the symphysis pubis anteriorly. The mass on the posterior aspect had involved the

rectum with loss of fat planes and on the lateral aspect had extended to the lateral pelvic wall. He also had computed tomography (CT) scan of thorax and isotope bone scan which did not reveal any metastasis. He underwent total pelvic exenteration with pelvic lymphadenectomy along with urinary and faecal diversion with ileal conduit and an end colostomy. The pelvic tumour was said to have been completely resected in two pieces in view of difficult dissection without any spillage and gross evidence at the end of the operation. The residual perineal aspect of the tumour was removed via an elliptical incision with a wide margin of normal tissue together with total penectomy. A margin of tissue was also excised from the anterior abdominal wall along with the cystotomy tract. At the end of the procedure, complete gross clearance was achieved with no palpable or visible disease. Histological examination of the surgical specimens revealed a mixture of carcinomatous and sarcomatous components which had comprised diffuse sheets and aggregate of oval and spindle shaped cells which were arranged in short interlacing fascicles with areas of chondroid, osteogenic, squamous differentiation. With regard to the immunohistochemistry profile of the tumour, cytokeratin AE1/AE3 and cytokeratin cam5.2 immunohistological studies were undertaken which revealed focal positivity and PSA staining was negative. Histological examination also showed that two recovered pelvic lymph nodes were involved by the tumour. The patient was alive and well without any evidence of recurrence at his 4 months follow-up based upon CT scan of abdomen, pelvis and thorax which he had. Nazim et al. [11] stated the following:

- Many postulates have been promulgated regarding the histogenesis of sarcomatoid carcinoma of prostate which include (1) simultaneous development of both sarcoma and carcinoma from different regions of the same prostate. (2) Dual differentiation of malignant precursor (totipotent as promulgated by Kubusawa et al. [12], (3) transformation of adenocarcinoma into sarcoma and vice versa as iterated by Quay et al. [13] and Lauwers et al [9], (4) de-differentiation of tumour as a result of the effect of hormonal or radiotherapy treatment as suggested by some authors [9], [14], [15] Nevertheless, loss-of-heterozygosity (LOH) analysis studies which had been undertaken on tissue samples had shown that both the malignant epithelial and mesenchymal components of sarcomatoid carcinoma were clonally related which would be in support of the hypothesis of a single malignant transformation process [16] [17]
- In their case, there was only adenocarcinoma in the original trans-urethral resected specimen of the prostate but the subsequent pelvic exenteration specimen contained adenocarcinomatous component mixed with sarcomatous component. Their patient did not receive hormonal therapy or radiotherapy. They would therefore postulate the histogenesis of the tumour to have emanated from transformation of adenocarcinoma of the prostate to the sarcomatous component.
- In most of the previously reported cases of sarcomatoid carcinoma of prostate, there was a history of prior adenocarcinoma of the prostate gland and the reported interval between the diagnosis of the original adenocarcinoma of prostate and the sarcomatoid

529 carcinoma was between 6 months and 16 years. [18] Nevertheless, in their case the  
530 interval was only 3 months which would indicate which would explain the very  
531 aggressive disease process.

532 • Previously reported cases of sarcomatoid carcinoma of prostate had shown the  
533 epithelial component of the tumour to be high-grade adenocarcinoma. It had been  
534 stated that [18] morphologically, the sarcomatoid component of carcinosarcoma had  
535 varied from 5% to 99% of the total tumour and the sarcomatoid components tend to  
536 be composed of undifferentiated spindle and pleomorphic cells which are arranged in  
537 fascicles and sheets. A variety of sub-types of sarcoma can also be found and these  
538 include osteosarcoma in 50% of cases, chondrosarcoma in 33% of cases, and  
539 leiomyosarcoma in 17% of cases, and rarely rhabdomyosarcoma, malignant fibrous  
540 histiocytoma and fibrosarcoma. [19] Their patient had, mostly un-differentiated sheets  
541 of large spindle cells with few areas of osteogenic, chondrogenic, and squamous  
542 differentiation.

543 • Most patients with carcinomatoid carcinoma of the prostate manifest with obstructive  
544 voiding symptoms. Dundore et al. [20] in a series of 21 patients reported that  
545 carcinosarcoma was subsequently diagnosed in 18 patients who had previously  
546 undergone TURP secondary to obstructive symptoms [20] An equal number of  
547 patients who are afflicted by sarcomatoid carcinoma of the prostate gland have normal  
548 and higher PSA levels.

549 • Fukawa et al. [21] had stated that sarcomatoid carcinoma of the prostate is associated  
550 with an aggressive course with local and systemic spread. As a result of extensive  
551 rapid growth, and about half of the patients subsequently develop urinary and faecal  
552 obstruction and severe pelvic or perineal pain as a sequel of involvement /  
553 compression of pelvic nerves.

554 • A number of treatment options including radiotherapy, hormonal treatment,  
555 chemotherapy and surgery been used in cases of sarcomatoid carcinoma of prostate  
556 with disappointing outcomes. Some authors [21] [22] of the opinion that surgical  
557 removal should be the first line therapy for sarcomatoid carcinoma of the prostate  
558 with potential cure. The aforementioned approaches depend upon the extent of the  
559 tumour and include radical surgery, [radical retro-pubic prostatectomy,  
560 cystoprostatectomy or pelvic exenteration. ]

561 Goto et al. [23] in 2010 reported a 75-year-old man who presented in 2008 with nocturia. His  
562 serum PSA level was 14.37 ng / ml (normal range 0.0 to 4.0 ng / ml). He had computed  
563 tomography (CT) scan of abdomen and pelvis which showed a large prostate which had  
564 invaded the rectum and urinary bladder. He had trans-rectal ultra-sound guided biopsy of  
565 prostate and histological examination of the specimen revealed a poorly differentiated  
566 adenocarcinoma of prostate. He was commenced on maximum androgen blockade and after  
567 one month his serum PSA level had remained within normal range. He then had magnetic  
568 resonance imaging (MRI) scan of pelvis which had shown that the prostate gland had



decreased in size; however, the mass invading the urinary bladder and the rectum had got larger [see figure 2a, b]. Six months after his initial presentation, he underwent pelvic evisceration for the carcinoma of prostate [see figure 2c]. Histological examination of the specimen revealed a poorly differentiated adenocarcinoma Gleason 4/5 in the prostate gland as well as an undifferentiated sarcomatoid carcinoma which had consisted of spindle cells arranged in fascicles in the arear of the posterior invasion of the tumour [see figures 3a-c]. The undifferentiated carcinoma component was found to contain numerous multi-nucleated giant cells. On immunological staining, the undifferentiated was positively stained for cytokeratin AE1/3, but negatively stained for cytokeratin 7, cytokeratin 20, vimentin, and PSA (see figure 3d). His follow-up serum PSA level had remained normal. Three months after the pelvic exenteration procedure the patient had a CT scan of thorax which had shown a small nodular shadow in his right lung [see figure 4a]. The authors stated that at the mediastinal window setting, the tumour in the right lung, showed a density similar to that of large vessels [see figure 4b]. The patient was continued on total androgen blockade but despite this the tumour in the right lung got bigger. He had Positron emission tomography (PET) scan which apart from showing abnormal fluorodeoxy glucose uptake in the small nodular shadow in the right lung it did not show any abnormality anywhere else. Eleven months after his initial presentation, he underwent bronchoscopy and thoracoscopic wedge resection nodular mass in the lung [see figure 5a]. The lung tumour was noted to have a surface that was covered with pleura, protruded into the pleural cavity in a polypoidal fashion [see figure 5a and 5b]. Histological examination of the specimen showed similar characteristics to the original sarcomatoid carcinoma of the prostate gland therefore a diagnosis of metastatic pulmonary sarcomatoid carcinoma ensuing primary sarcomatoid carcinoma of the prostate was made [see figure 5c and 5d]. Numerous multi-nucleated giant cells were also seen and there evidence of good microvasculature in the tumour on microscopic examination. Immunohistological staining of the tumour showed positive staining cytokeratin AE1/AE3 and negative staining for cytokeratin 7, cytokeratin 20, vimentin, and PSA [see figure 5e]. The patient next received combination systemic chemotherapy with cisplatin, ifosfamide, and Adriamycin. He was alive and free from tumour recurrence 10 months following his lung surgery. The authors stated that their case was the first case of solitary pulmonary metastasis from sarcomatoid carcinoma of the prostate to be reported in the literature.

Huan et al. [24] reported two patients who had conventional adenocarcinoma of the prostate gland who then subsequently developed sarcomatoid carcinoma of the prostate gland six and two and half years following radiotherapy treatment (seed implant and external beam) for the original adenocarcinoma of prostate. They stated the following:

- Their cases had histological characteristics that were consistent with cases that were previously reported in the literature. The tumours were composed of spindle cells with large hyperchromatic nuclei and a pattern which resembled sarcoma.
- Immunohistochemical staining of the tumours had shown that the tumours were weakly positive for EMA, CK7, and vimentin, Ki67 staining had shown positive



610 staining in more than 50% of the tumour cells. The tumours also did stain diffusely  
611 positive for p53 and p63. PSA and PAP were negative.

- 612 • Clinically, in their opinion, the sarcomatoid carcinomas,
- 613 • had appeared to have originated from the prostate gland.
- 614 • The pathogenesis of the tumours was still uncertain; nevertheless, they most likely  
615 represented a radiotherapy-induced dedifferentiation of adenocarcinoma of the  
616 prostate gland.

617 There is no consensus opinion regarding the best treatment option; nevertheless, it would  
618 appear that early diagnosis and early aggressive surgical treatment in the form of radical  
619 prostatectomy or anterior pelvic exenteration and an adjunctive therapy using systemic  
620 chemotherapy might help improve prognosis. There are perhaps a large number of SCPs  
621 which are not detected because clinicians do not look for them considering the fact that a  
622 large number of patients who have been treated for adenocarcinoma of prostate by means of  
623 hormonal treatment or radiotherapy subsequent progression of disease and castrate resistant  
624 carcinoma of prostate following initial response to hormonal therapy. There is evidence to  
625 suggest that PSCP may develop following hormonal treatment as well as following  
626 radiotherapy for adenocarcinoma of prostate. It would be argued that a large number of  
627 patients who have developed castrate resistant prostate cancer following hormonal therapy  
628 and those who have developed progressive prostate cancer may have developed  
629 dedifferentiation into sarcomatoid carcinoma, angiosarcoma, small cell carcinoma admixed  
630 with adenocarcinoma but cannot be ascertained unless further biopsies are taken when a  
631 diagnosis of castrate resistant cancer is made or a diagnosis of progress of the carcinoma is  
632 made after radiotherapy. It would further be argued that if biopsies of prostate are undertaken  
633 for most patients who have developed castrate resistant carcinomas of prostate as well as  
634 those whose tumours have progressed after radiotherapy perhaps a large number of new  
635 carcinomas which had emanated from dedifferentiation would be diagnosed including  
636 sarcomatoid carcinoma of the prostate. In that case it would be argued that patients who are  
637 found to have developed PSCP following radiotherapy should be considered for  
638 chemotherapy plus or minus radical surgery if the patients are fit to undergo surgery. In order  
639 to confirm or negative these arguments a large scale multi-centre trial would be  
640 recommended to help decide on the best treatment options for PSCP and another trial to  
641 determine the proportion of patients who develop progressive disease or castrate resistant  
642 prostate carcinoma who have developed dedifferentiation into PSCP or any other variant of  
643 carcinoma of prostate.

## 644 **Conclusions**

645 PSCP is rare and may present with lower urinary tract symptoms and occasionally with  
646 perineal pain and / or haematuria. PSCP may develop de novo or pursuant to previous  
647 radiotherapy to hormonal treatment or radiotherapy for adenocarcinoma of prostate. PSCP is  
648 an aggressive disease with the whole poor eventual outcome in majority of cases. Perhaps  
649 early diagnosis and early aggressive surgical treatment in the form of radical prostatectomy

or anterior pelvic exenteration and an adjunctive therapy using systemic chemotherapy might help improve prognosis. Early re-biopsies of prostate in cases of progressed carcinomas of prostate following radiotherapy and of castrate resistant carcinomas may perhaps help diagnose many carcinomas that have dedifferentiated into other variants of prostate cancer which may also in deciding of the best options of further management. Clinicians should enter all cases of PSCP they encounter into a global large-scale multi-centre trial in order to determine the best treatment options for PSCP and to further study the biological behaviour of PSCP.

## References

- [1] Arora K. Prostate other carcinomas Carcinosarcoma. Pathology Outlines.com 2012 Mar 22
- [2] Açıkgoz O, Gazel E, Zengin E Z, Kasap Y, Çamtosun A, Yazicioglu A H. Sarcomatoid Carcinoma of the Prostate. Case Reports in Urology.2013; Article ID 631809, 3 pages <http://dx.doi.org/10.1155/2013/631809>
- [3] Hansel D E, Epstein J I. Sarcomatoid carcinoma of the prostate: a study of 42 cases. Am. J Surg Pathol 2006 Oct; 30(10): 1316 – 1321
- [4] Adekoyejo Abiodun P, Adetola D, Charles A, Kehinde Habbeb T, Martins M. Sarcomatoid Carcinoma of Prostate: A Rare Entity. Journal of Case Reports 2014; 4: 33 – 37 <http://dx.doi.org/10.17659/01.2014.0009>
- [5] Wick M R, Young R H, Maivesta R, Beebe D S, Hansen J J, Denner L P. Prostatic carcinosarcomas. Clinical, histologic, and immunohistochemical data on two cases, with a review of the literature.Am J Clin Pathol 1989 Aug; 92(2): 131 - 139
- [6] Zizi-Sermpetzoglou A, Savvaidou V, Tepelenis N, Galariotis N, Olympitis M, Stamatiou K. Sarcomatoid carcinoma of the prostate: a case report. International Journal of Clinical and Experimental Pathology 2010; 3(3): 319 – 322
- [7] Eble J N, Sauter G, Ebstein J I, Sesterhenn I A. Pathology and Genetics of Tumors of the Urinary System and Male Genital Organs, IARC Press, 2004
- [8] Grignon D J. Unusual subtypes of prostate cancer. Modern Pathology 2004; 17(3): 316 – 327
- [9] Lauwers G Y, Schevchuk M, Armenakas N, Reuter V F. Carcinosarcoma of the prostate Am. J Surg Pathol 1993 Apr; 17(4): 342 – 349
- [10] Diao R, Fok K L, Zhang Z, Zhao L, Mou L, Sun S, Zhou L, Cai Z. Concurrence of squamous cell carcinoma, sarcomatoid carcinoma and adenocarcinoma in relapsed prostate cancer originated from adenocarcinoma. B. J. U. I. 2013 Mar 19; [www.bjui.org/ContentFullItem.aspx?](http://www.bjui.org/ContentFullItem.aspx?)

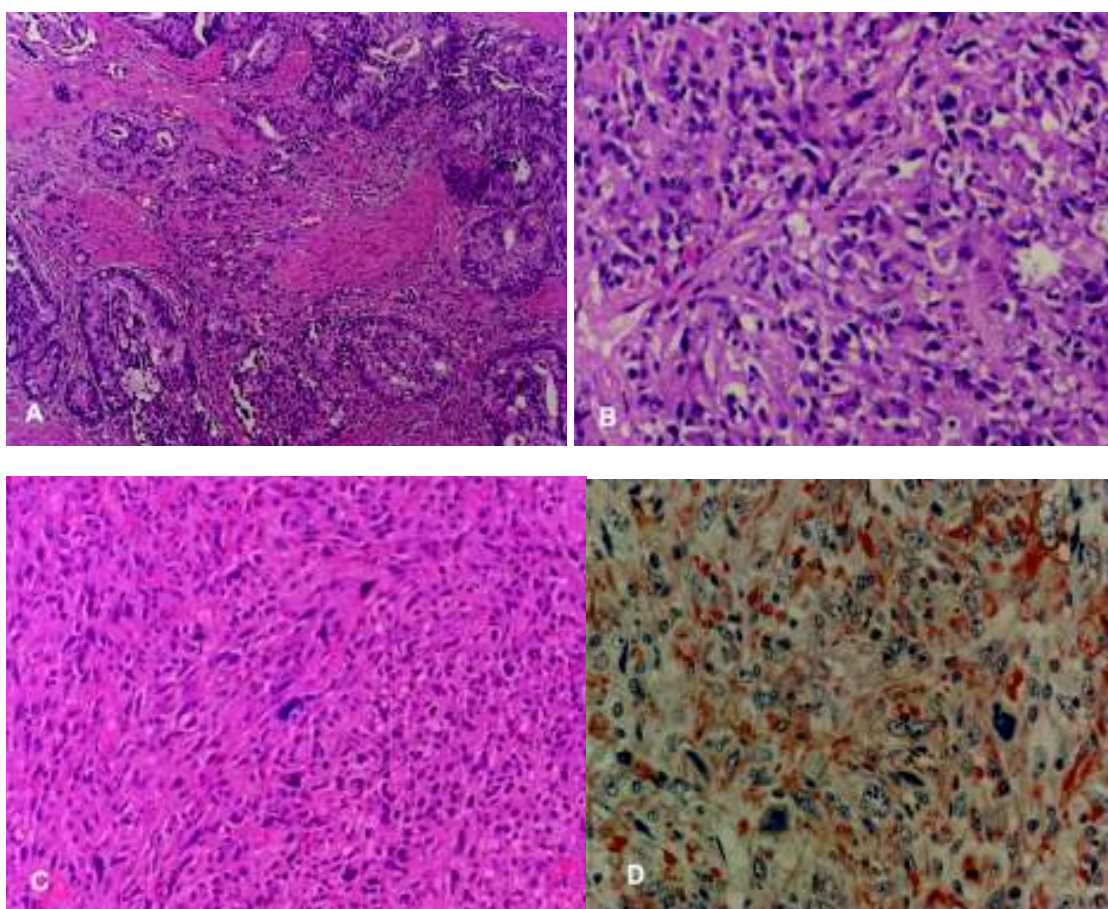
- 688 [11] Nazim S M, Jalbani I K, Abbas F, Minhas K Sarcomatoid carcinoma of  
689 prostate involving the whole lower urinary tract and rectum Case Report 2013;  
690 5(4): 283 – 286
- 691 [12] Kubosawa H, Matsuzaki O, Kondo Takao Sato N, Carcinosarcoma of the  
692 prostate. ActaPathoJpn.1993; 43: 209 -214
- 693 [13] Quay S C, Proppe K H. Carcinosarcoma of the prostate: Case report and  
694 review of the literature. J Urol. 1981; 125: 436-438
- 695 [14] Mostofi F K, Price E B., Jr., Atlas of Tumor Pathology. Series 2, Fascicle  
696 8 Washington D C. Armed Forces Institute of Pathology 1973; Tumors of the  
697 male genital system; pp. 177 – 258
- 698 [15] Sak S D,Orhan D, Yaman O, Tulunay O, Ozdiler E. Carcinosarcoma of  
699 the prostate: A case report and a possible evidence on the role of hormonal  
700 therapy. Urol. Int. 1997; 59: 50 – 52
- 701 [16] Ray M E, Wojno K J, Goldstein N S, Olson K N B, Shah R B, Cooney K A, Clonality of  
702 sarcomatous and carcinomatous elements in sarcomatoid carcinoma of the prostate. Urology.  
703 2006; 67: 423 e8
- 704 [17] Eble J N, Sauter Epstein J I. Sesterhenn I A , editors.Vol. 160. Lyon, France. IARC  
705 Press 2004.The World Health Organization Classification of Tumors of the Urinary System  
706 and Male Genital Organs pp. 209 – 211
- 707 [18] Hansel D E, Herawi M, Montgomery E, Epstein J I. Spindle cell lesions of  
708 the adult prostate. Mod Pathol. 2007; 20: 148 – 158
- 709 [19] Subramanian V S, Coburn M, Miles E J, Carcinosarcomas of the prostate  
710 with multiple metastases: Case report and review of the literature. Urol. Oncol.  
711 2005; 23: 181 – 183
- 712 [20] Dundore P A, Cheville J C, Nascimento A G, Farrow G M, Bostwick D  
713 G. Carcinosarcoma of the prostate: Report of 21 cases. Cancer 1995; 76: 1035-  
714 1042
- 715 [21] Fukawa T, Numata K, Yamanaka M, Miyamoto T, Kurokawa Y,  
716 Kanayama H O. et al. Prostatic carcinosarcoma: A case report and review of  
717 the literature. Int. J Urol. 2003; 10: 108 – 113
- 718 [22] Mazzucchelli R, Lopez-Beltran A, Cheng L, Scarpelli M, Kirkali Z,  
719 Montironi R. Rare and unusual histological variants of prostatic carcinoma:  
720 Clinical significance. B. J. U. Int. 2008; 102: 1369 – 1374
- 721 [23] Goto T, Maeshima A, Oyamada Y, Kato R. Solitary pulmonary  
722 metastasis from prostate sarcomatoid cancer. World Journal of Surgical  
723 Oncology 2010; 8: 101 doi: 10.1186/1477-7819-8-101

[24] Huan Y, Idrees M, Gribetz M F, Unger R D. Sarcomatoid carcinoma after radiation treatment of prostatic adenocarcinoma. *Annals of Diagnostic Pathology* 2008 Apr; 12(2): 142 – 145

Figure 1: (a) Gleason 5 + 3 = 8 prostate adenocarcinoma in the pathological examination of the first TUR-P material (an area which has more glands). (b) Undifferentiated tumour cells in pathological examination of the second TUR-P material. (c) Sarcomatous areas in the last TUR-P material (spindle and rare bizarre cells). (d) Sarcomatoid cells in immunohistochemical examination (Vimentin positive / AEC chromagen). Reproduced from: [2] AçJkgöz O, Gazel E, Zengin E Z, Kasap Y, Çamtosun A, Yazicioglu A H. Sarcomatoid Carcinoma of the Prostate. *Case Reports in Urology*.2013; Article ID 631809, 3 pages <http://dx.doi.org/10.1155/2013/631809> Copy Right © 2013 Onur AçJkgöz This is an open access article distributed under the Creative Commons Attribution License which permits unrestricted use, distribution, and reproduction in any medium, provided the original work is properly cited.

[a]

[b]



746 [c] [d]

747

748

749

750

751 Figure 2

752 Radiological and microscopic findings of prostate cancer: A-B, Pelvic MRI  
 753 showed an enlarged prostate invading the bladder (arrow) and a polypoid mass  
 754 invading the rectum (arrowhead) (A, T1-weighted sagittal view; B, T2-  
 755 weighted axial view). C, Gross examination of the resected specimen revealed  
 756 an enlarged prostate invading the bladder (arrow) and polypoid mass invading  
 757 the rectum (arrowhead) Reproduced from: Goto et al. World Journal of  
 758 Surgical Oncology 2010; 8: 101 doi: 10.1186/1477-7819-8-101 © Goto et al;  
 759 licensee Bio Med Central Ltd. This is an Open Access article distributed under  
 760 the Creative Commons Attribution License  
 761 (<http://creativecommons.org/licenses/by/2.0>), which permits unrestricted use,  
 762 distribution and reproduction in any medium provided the original work is  
 763 properly cited. The copy Right is permanently retained by Bio Med Central  
 764 Ltd on behalf of the journal and the authors.



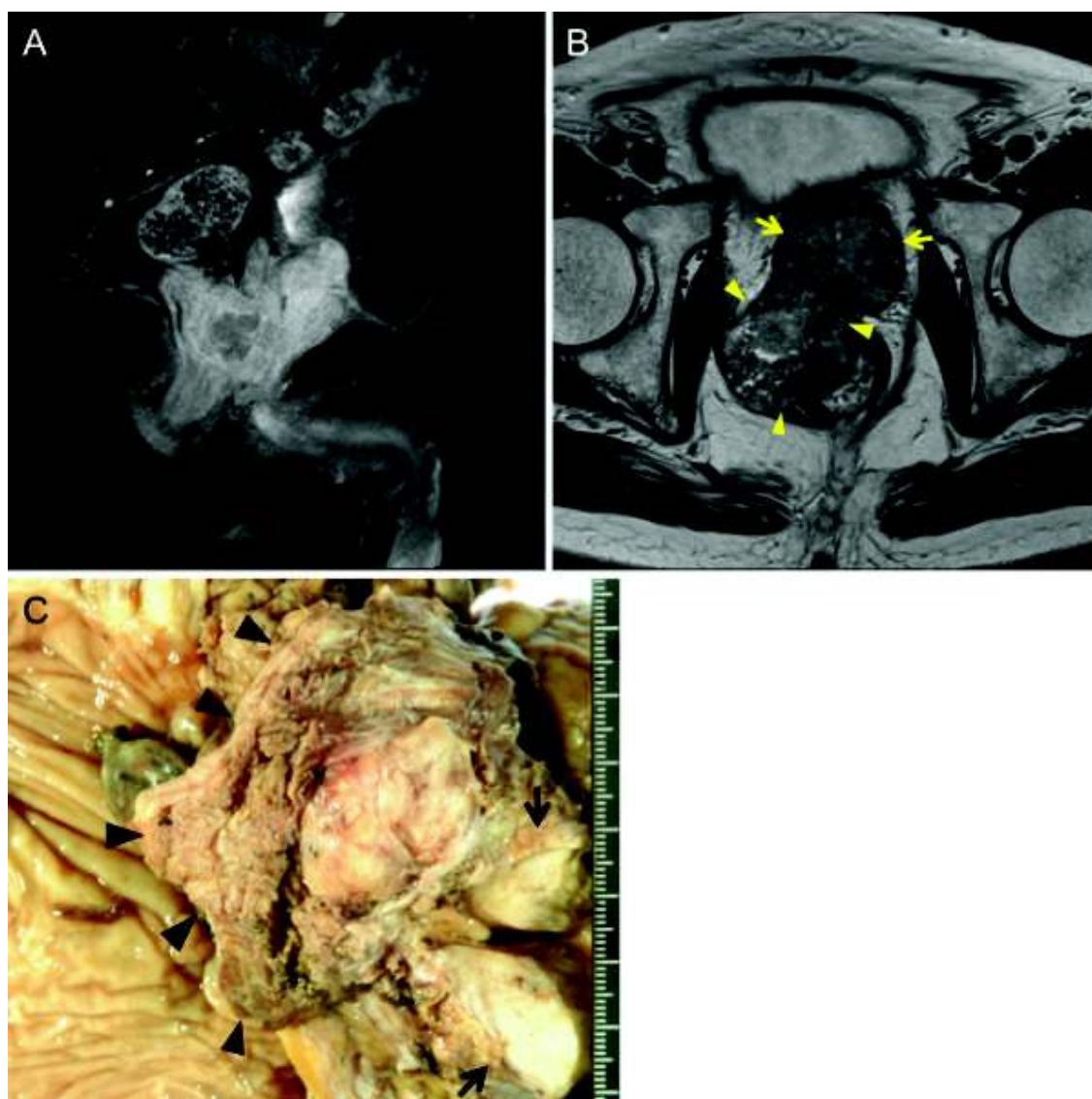


Figure 3

Histological findings of prostate cancer: A, The tumor was composed of a poorly differentiated Gleason 4/5 adenocarcinoma (lower left of photograph) and an undifferentiated sarcomatoid carcinoma (upper right of photograph). B, The intraprostatic tumor showing a mixture of cribriform structures and necrosis C, The tumor in the area of posterior invasion Arrows indicate multinucleated giant cells. D, Cytokeratin AE1/3 immunostaining of the sarcomatoid carcinoma component Reproduced from: Goto et al. World Journal of Surgical Oncology 2010; 8: 101 doi: 10.1186/1477-7819-8-101 © Goto et al; licensee Bio Med Central Ltd. This is an Open Access article distributed under the Creative Commons Attribution License (<http://creativecommons.org/licenses/by/2.0>), which permits unrestricted use, distribution and reproduction in any medium provided the original work is

properly cited. The copy Right is permanently retained by Bio Med Central Ltd on behalf of the journal and the authors.

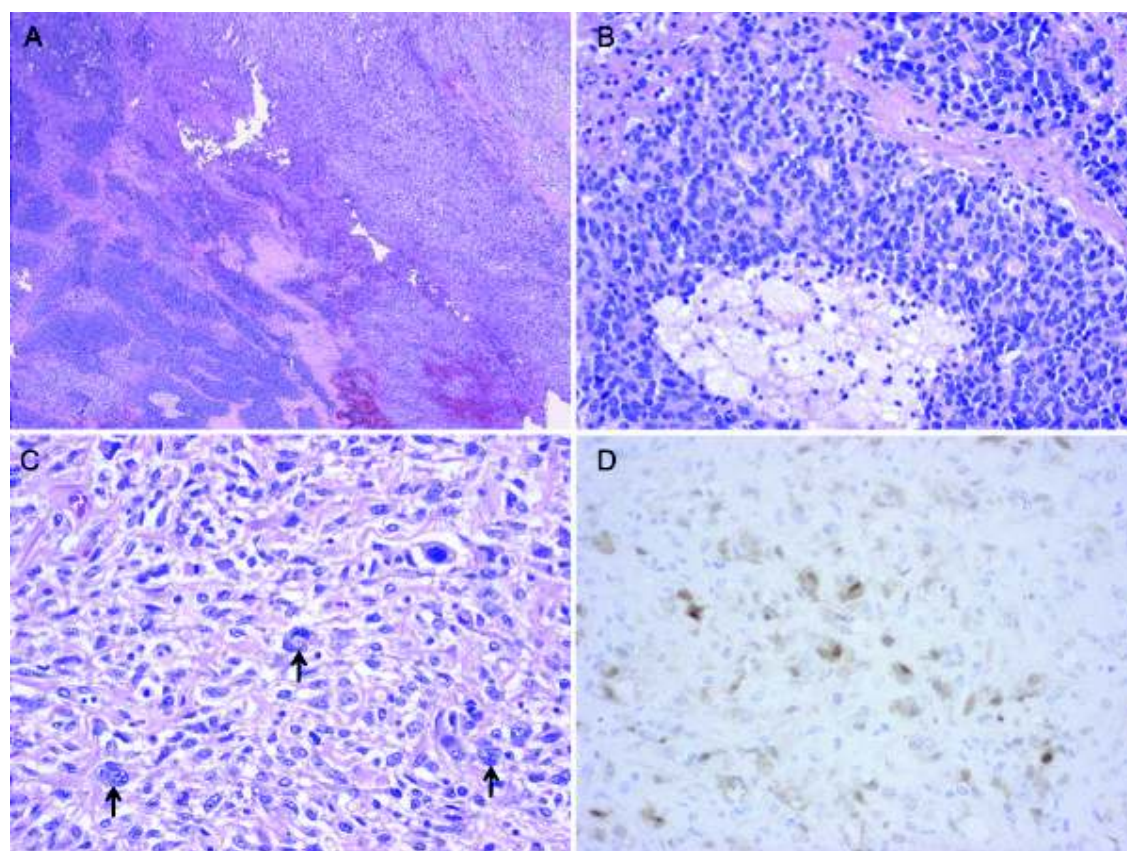
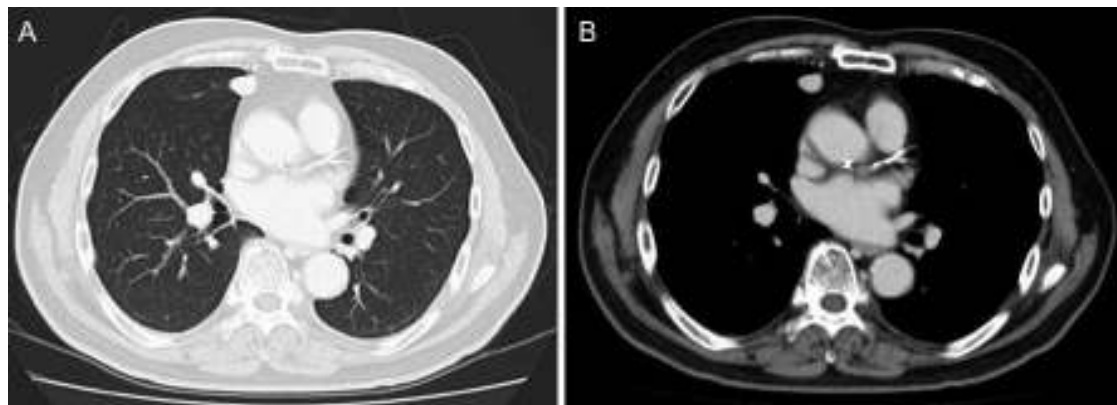


Figure 4

CT findings of solitary pulmonary metastasis: A-B, after pelvic evisceration, Chest CT revealed a small nodular shadow (A, lung window image; B, mediastinal window image). Reproduced from: Goto et al. World Journal of Surgical Oncology 2010; 8: 101 doi: 10.1186/1477-7819-8-101 © Goto et al; licensee Bio Med Central Ltd. This is an Open Access article distributed under the Creative Commons Attribution License (<http://creativecommons.org/licenses/by/2.0>), which permits unrestricted use, distribution and reproduction in any medium provided the original work is



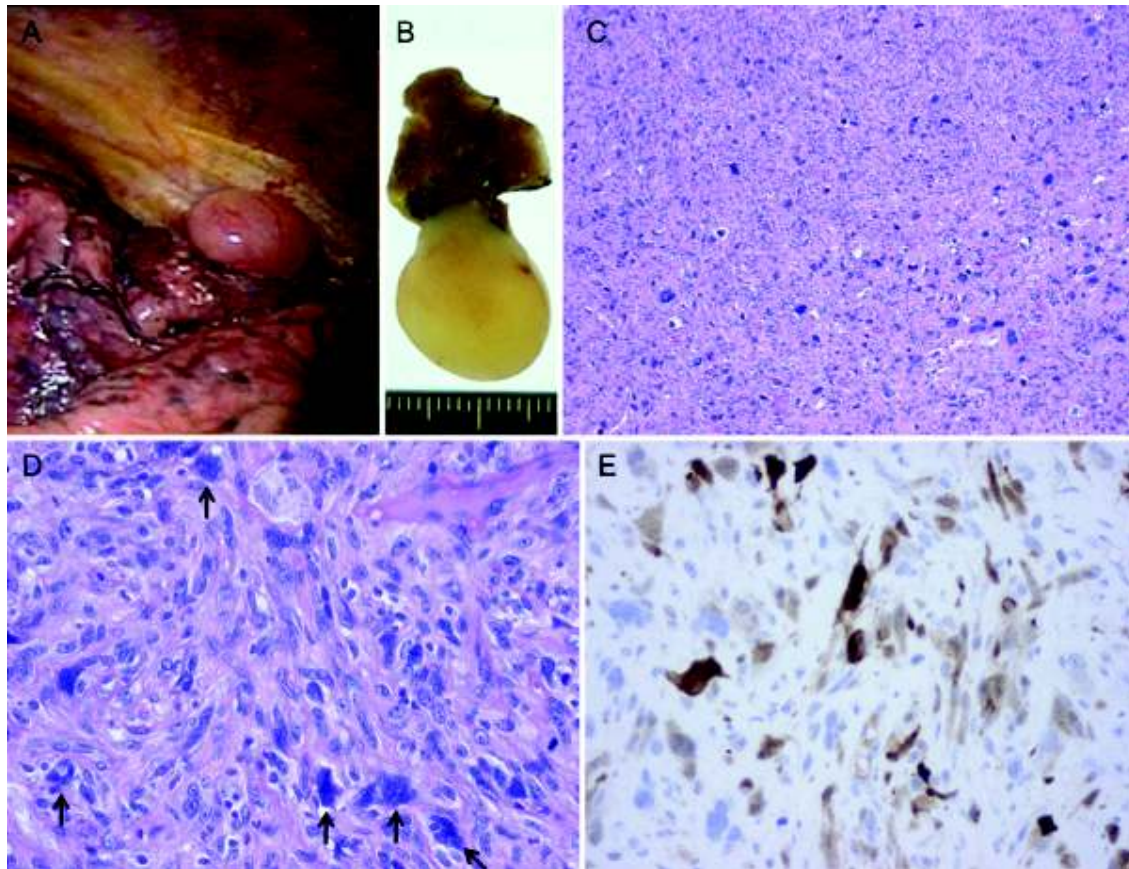
properly cited. The copy Right is permanently retained by Bio Med Central Ltd on behalf of the journal and the authors.



**Figure 5 Pulmonary metastasis of prostate cancer.** A, Gross appearance during thoracoscopic surgery; B, Gross appearance of the resected specimen; C-D, Histology of the lung tumor Arrows indicate multinucleated giant cells; E, Cytokeratin AE1/3 immunostaining of the lung tumor. Reproduced from: Goto et al. World Journal of Surgical Oncology 2010; 8: 101 doi: 10.1186/1477-7819-8-101 © Goto et al; licensee Bio Med Central Ltd. This is an Open Access article distributed under the Creative Commons Attribution License (<http://creativecommons.org/licenses/by/2.0>), which permits

829 unrestricted use, distribution and reproduction in any medium provided the  
 830 original work is properly cited. The copy Right is permanently retained by Bio  
 831 Med Central Ltd on behalf of the journal and the authors.

832



833  
 834

835