Case Study

Leiomyosarcoma of the kidney: case report and brief literature review

Abstract:

Primary leiomyosarcoma of the kidney is a rare tumor with an aggressive behavior. However, reported literature is very limited. We report a case of renal leiomyosarcoma in a 46 years old woman presenting with a left sided abdominal mass. Computed tomography scan of the abdomen revealed the mass to be renal in origin and involving the ipsilateral renal hilus and vein. Microscopy reflected a malignant spindle cell neoplasm which showed strong reactivity for smooth muscle actin with negative epithelial markers, thereby confirming the diagnosis of renal leiomyosarcoma. Induction chemotherapy was indicated. After two cycles, the patient died of disease progression. Renal leiomyosarcomas have a very poor prognosis, radical nephrectomy should be the primary therapeutic method to offer the best chances of cure.

Introduction:

Renal sarcomas constitute only 1-2% of malignant renal tumors in adulthood [1]. Of these, 50 – 60% are leiomyosarcomas [2]. However, the reported literature is very limited, and to the best of our knowledge, this is one of the few reported cases.

Case report:

A 46-year-old woman presented with large palpable mass on the left side of the abdomen with pain in the flank and abdomen for last three months. She had no haematuria, fever, or history of bowel disturbances. Her past medical history was not relevant. On clinical examination, the patient was hemodynamically stable with a palpable left lumber mass, extending to left hypochondrium and umbilical region. Initial laboratory workup revealed a normocytic hypochromic anaemia. The biochemical investigations were all within normal range. Computed tomographic scan showed a large heterogeneous left renal mass measuring 23 x 18 x 13cm, and involving ipsilateral renal hilus and vein with no evidence of distant metastases (Figure 1). Renal biopsy was performed. Pathology revealed a malignant tumor composed of spindle cells arranged in fascicles and plexiform pattern, with marked nuclear pleomorphism and prominent nucleoli with acidophilic cytoplasm (Figure 2a,b). The mitotic rate was high (16/10 HPF). A diagnosis of renal leiomyosarcoma was made which was confirmed with positive immunostaining for smooth muscle actin while they were negative for cytokeratin (Figure 2c). Induction chemotherapy based on doxorubicin (60mg/m^2) and ifosfamide (9g/m^2) every 3 weeks was indicated to render tumor resectable with clear margins. Unfortunatly, the patient succumbed to complications of locoregional disease progression after two courses of chemotherapy.

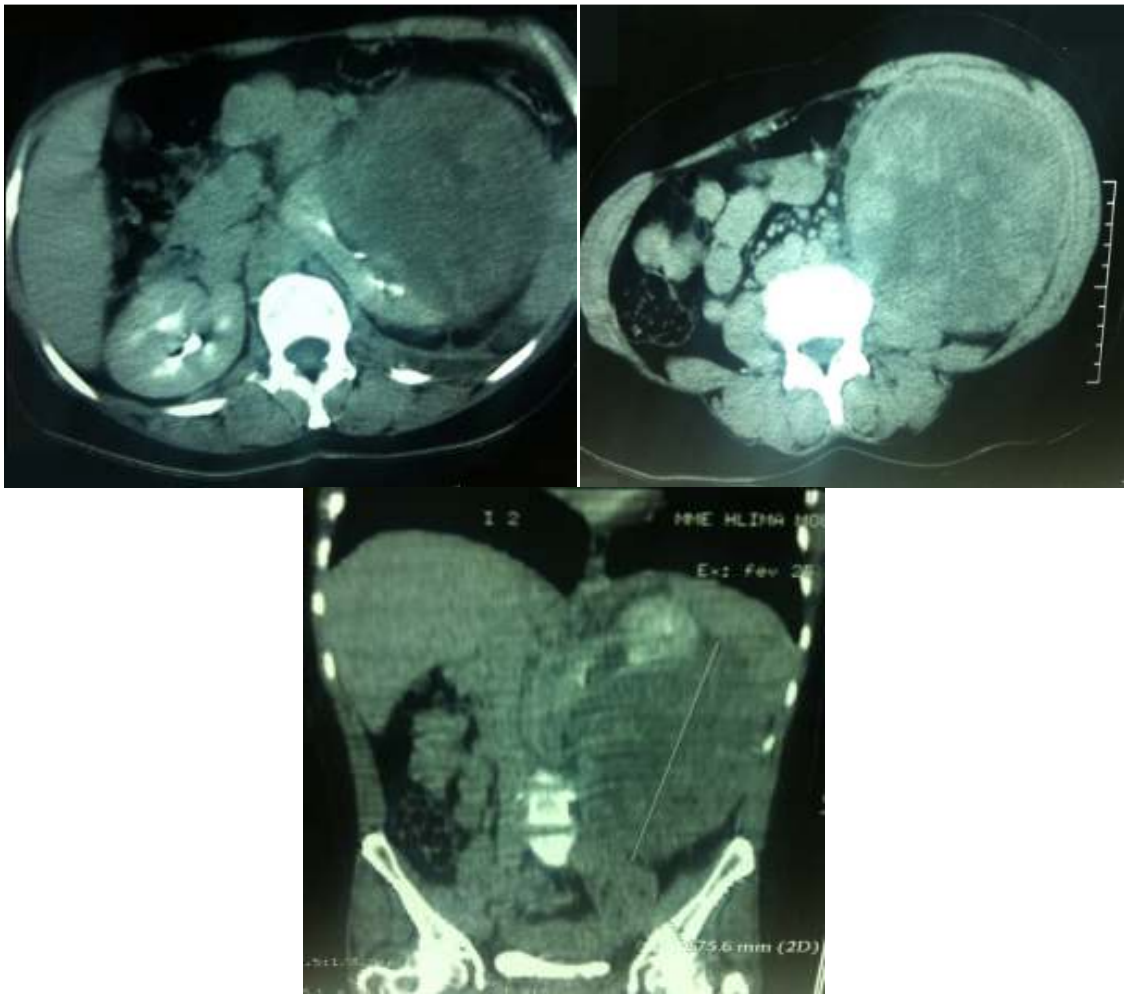

Figure 1: Computed tomography of abdomen showing kidney with large heterogenous mass lesion involving the ipsilateral hilus.

(a) 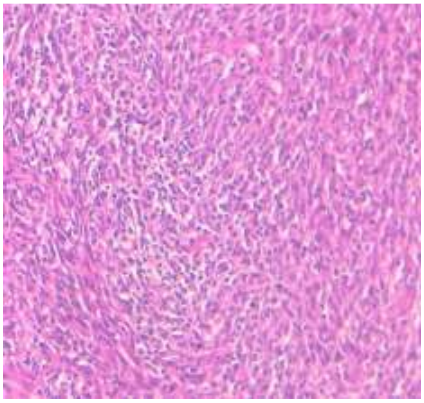 (b) 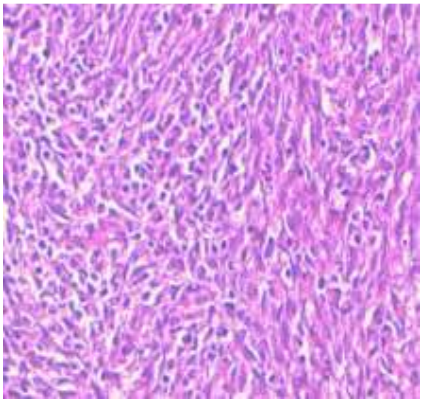

(c) 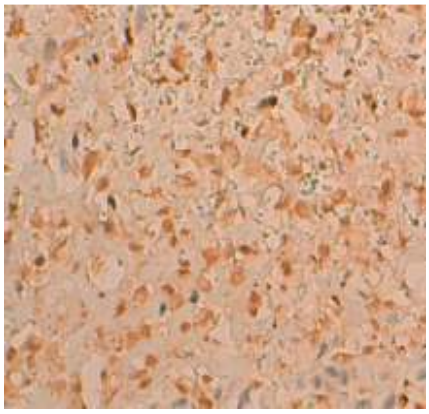

Figure 2: (a) and (b) Hematoxylin and eosin staining demonstrating spindle cell neoplasm arranged in fascicles and plexiform pattern with marked nuclear pleomorphism and acidophilic cytoplasm (X 10, 20 respectively). (c) Immunohistochemical stains showing positivity for smooth muscle actin.

Discussion:

Leiomyosarcomas are malignant neoplasms of smooth muscle origin. Apart from the uterus, soft tissue leiomyosarcoma commonly occurs in the retroperitoneum, and usually involves the lower extremity but they can occur in the head and neck region also [3]. Primary leiomyosarcomas are rare in the kidney and constitute 1-2% of all malignant renal tumors [1] but are the commonest renal sarcoma. However, only 27 cases were identified during a 23-year period at 3 large institutions attesting to its exceeding rarity [4].

Primary leiomyosarcoma of the kidney has preponderance in women and is more frequent in fourth decade of life but can be found in almost any age group, with a gradually increasing incidence in the later period of life [5]. Histogenesis of renal leiomyosarcomas is believed to be from the renal capsule or the smooth muscle fibres in the renal pelvis or from the renal vessels [5]. The most common clinical symptoms are pain, palpable mass and hematuria, all of which are indicators of an extensive local disease [6,7]. Retroperitoneal leiomyosarcoma secondarily involving the kidney must be ruled out before diagnosing primary renal leiomyosarcoma. Furthermore, the treatment options are the same for both lesions such that the clinical distinction becomes, in some instances, somewhat of an academic exercise.

Grossly, renal leiomyosarcoma may appear as evident trabeculations and wholing patterns. Microscopically, the tumor shows alternating fascicles of spindle shaped cells with marked nuclear atypia and prominent mitotic figures. They are distinguished from renal leiomyomas by cellular pleomorphism, increased mitotic rate, and the presence of cellular necrosis. On immunohistochemistry, they show a positive reaction to smooth muscle markers like smooth muscle actin with negative cytokine markers.

Resection is the standard treatment for these aggressive lesions, many urologists and oncologists have advocated radical nephrectomy followed by either chemotherapy or radiation [9,10,11]. The role of adjuvant chemotherapy/radiotherapy remains obscure due to paucity of data on treatment of this rare renal neoplasm and the majority of patients develop metastatic disease regardless of treatment. In general, chemotherapy for advanced leiomyosarcoma is not successful. In a study of 34 advanced leiomyosarcomas (29 uterine), 53% had some response to gemcitabine and docetaxel; yet the median survival was still only 17.9 months [12]. Therapeutic responses have also been observed with anthracyclines, Ifosfamide[13], and temozolomide [14].

Renal leiomyosarcomas have a very poor prognosis because of aggressive behaviour owing to rapid growth rate, and high potential for metastasis. Most patients die within 1 year after diagnosis [15].

CONCLUSION

Early recognition and aggressive surgery are the keys to long-term survival of patients with renal leiomyosarcomas, but the mainstay of treating advanced disease is yet to be determined and needs further research as the overall prognosis of advanced disease is relatively poor.

[1]. A. Demir, C. M. Yazici, F. Eren, and L. T¨urkeri, “Case report: good prognosis in leiomyosarcoma of the kidney,” International Urology and Nephrology, vol. 39, no. 1, pp. 7–10, 2007.

[2]. Srinivas V, Sogani PC, Hajdu SI, Whiteore WF. Sarcomas of the kidney. J Urol. 1984;132:13-16.

[3]. C. A. Angel, L. L. Gant, D. M. Parham, B. N. Rao, E. C. Douglass, and T. Lobe, “Leiomyosarcomas in children: clinical and pathologic characteristics,”

[4]. Jeremy S. Miller, Ming Zhou, Fadi Brimo, Charles C. Guo and Jonathan I. Epstein. Primary Leiomyosarcoma of the Kidney: A Clinicopathologic Study of 27 Cases. Am J Surg Pathol 2010;34:238–242.

[5]. Niceta P, Lavengood RW Jr, Fernandes M, Tozzo PJ. Leiomyosarcoma of kidney: review of the literature. Urology.1974; 3:270-7.

[6]. Kavantzas N, Pavlopoulos PM, Karaitianos I, Agapitos E. Renal leiomyosarcoma: report of three cases and review of the literature. Arch Ital Urol Androl. 1999; 71:307-11.

[7]. Lacquaniti S, Destito A, Candidi MO, Petrone D, Weir JM, Servello C, et al. Two atypical cases of renal leiomyosarcoma: clinical picture, diagnosis and therapy. Arch Ital Urol Androl 1998; 70:199-201.

[8]. A. T. Deyrup, E.Montgomery, andC. Fisher, “Leiomyosarcoma of the kidney: a clinicopathologic study,” American Journal of Surgical Pathology, vol. 28, no. 2, pp. 178–182, 2004.

[9]. Lehnhardt M, Muehlberger T, Kuhnen C, et al. Feasibility of chemosensitivity testing in soft tissue sarcomas. World J Surg Oncol. 2005;3:20.

[10]. Moureau-Zabotto L, Thomas L, Bui BN, et al. Management of soft tissue sarcomas in first isolated local recurrence: a retrospective study of 83 cases. Cancer Radiother. 2004;8:279–287.

[11]. Youssef E, Fontanesi J, Mott M, et al. Long-term outcome of combined modality therapy in retroperitoneal and deep-trunk softtissue sarcoma: analysis of prognostic factors. Int J Radiat Oncol Biol Phys. 2002;54:514–519.

[12]. Maki RG. Gemcitabine and docetaxel in metastatic sarcoma: past, present, and future. Oncologist. 2007;12:999–100

[13]. Kroep JR, Ouali M, Gelderblom H, et al. First-line chemotherapy for malignant peripheral nerve sheath tumor (MPNST) versus other histological soft tissue sarcoma subtypes and as a prognostic factor for MPNST: an EORTC soft tissue and bone sarcoma group study. Ann Oncol 2011; 22:207.

[14]. Garcia del Muro X, Lopez-Pousa A, Martin J, et al. A phase II trial of temozolomide as a 6-week, continuous, oral schedule in patients with advanced soft tissue sarcoma: a study by the Spanish Group for Research on Sarcomas. *Cancer*. Oct 15 2005;104(8):1706-12.

[15]. Dominici A, Mondaini N, Nesi G, Travaglini F, Di Cello V, Rizzo M. Cystic leiomyosarcoma of the kidney: an unusual clinical presentation. Urol Int. 2000;65(4):229-231.