Original research article

DETECTION OF EBV AND HPV IN ORAL SQUAMOUS CELL CARCINOMA AND AMELOBLASTOMA: REAL TIME POLYMERASE CHAIN REACTION STUDY

[1]Hosny Badrawy,[2] Ahmed Abd-Elmagid, [3]Mohamed Hosam, [4]Hanan Eid

[1] Associate professor of clinical pathology, South Egypt cancer Institute, Assiut University, Assiut, Egypt

[2] Professor of oral pathology, Faculty dentistry, Menia University, Menia, Egypt

[3] Professor of oral pathology, Faculty ofdentistry, Ain shams, University, Cairo Egypt

[4] Associate lecturer of oral pathology, Faculty of dentistry, Menia University, Menia, Egypt

Abstract

Background: Head and neck cancer includes several malignancies that originate in the paranasal sinuses, nasal cavity, salivary glands, oral cavity, pharynx, and larynx. The burden of viral infections in cancer is high but underappreciated by much of the cancer research community. Human papilloma virus infection has been postulated to be somehow involved in ameloblastoma etiopathogenesis. . Some sudies suggest an association between the presence of viral DNA and aggressive of certain cancers The purpose of this study was to examine the association between HPV and EBV with oral squamous cell carcinoma and ameloblastoma assessed by detection of their DNA in these tissues and to correlate the presence of the viral DNA and aggressiveness of these tumors.

Methods: Thirty formalin fixed and paraffin embedded blocks were used in the study. Fifteen of them were previously diagnosed as oral squamous cell carcinoma and the others fifteen were previously diagnosed as ameloblastoma and all of them underwent examination for EBV and HPV by real time PCR.

Results: HPV was detected among 2/15 (13.3%) of squamous cell carcinoma cases and in 4/15 (26.6%) of ameloblastoma while EBV was detected among 3/15 (20%) of squamous cell carcinoma cases and in 4/15 (26.6%) in ameloblastoma.

Conclusion: The current study may provides a role of HPV and EBV infection in the etiology of oral SCC and HPV might be implicated in the etiology of ameloblastoma and hence in malignant transformation of this tumor.

Keywords: Human papilloma virus, Epstein barr virus, oral cancer

Introduction:

Head and neck cancer (HNC) includes several malignancies that originate in the paranasal sinuses, nasal cavity, salivary glands, oral cavity, pharynx and larynx [1]. HNC is the seventh most common type of cancer in the world . HNC accounts for an estimated 130,000 new cases every year [2]. Odontogenic tumors arise from epithelial, ectomesenchymal or mesenchymal elements that are parts of the tooth forming apparatus. Ameloblastoma(AB) is a common odontogenic neoplasm account to 36% of all odontogenictumors in China [3]. Although classified as benign, its local invasion, distant metastasis and malignant transformation pose a therapeutic challenge in oral and maxillofacial surgery [4]. The burden of viral infections in cancer is high but underappreciated by much of the cancer research community. The International Agency for Research on Cancer (IARC) estimates that one in five cancer cases worldwide are caused by infection mostly by viruses [5,6]. These cancers are particular public health problems for the developing world, as well as for underserved and immunosuppressed populations in developed countries. Most importantly, these cancers have readily identifiable targets for diagnosis, prevention and therapy. Vaccination programs against two human tumor

viruses , hepatitis B virus (HBV) and human papilloma virus (HPV) , have already began to alter ageold cancer patterns on an international scale [7,8].

The role of HPV in cervical cancer was postulated, it is well established how this heterogeneous virus family represents an important human carcinogen, causing not only the vast majority of cervical and ano-genital tumors, but also a variable number of cancers in other regions of the human body including the head and neck. In females, HPV infections ,on a global scale , account for more than 50% of infection-linked cancers; in males they are responsible for barely 5% [9].

Molecular methods such as PCR and in situ hybridization have detected EBV in many cancer including oral cancer [10].

Aims of the study:

The aims of this study are:

- To examine the association of HPV and EBV with OSCCs and AB assessed by detecting of their DNA in these tissues.
- To correlate the presence of viral DNA with aggressiveness of these tumors.

Materials and methods:

A total of 30 cases were used in this study (15 oral sqaumous cell carcinoma and 15 ameloblastoma) were taken from formalin- fixed, paraffin-embedded tissues from the files of the Oral Pathology Department , Faculty of Medicine, Minia University and the National Cancer Institute , Cairo University.

The study was performed after obtaining approval from the local Institutional Review Board Committee and in accordance with the Declaration of Helsinki, the Good Clinical Practices, and local ethical and legal requirements. All patients provided written informed consents

The squamous cell carcinoma cases were categorized as five: well differentiated, seven moderately differentiated and three poorly differentiated. While AB cases were categorized as eleven benign cases (5 plexiform , 4 follicular and 2 desmoplastic) and four malignant cases.

DNA was extracted from formalin fixed and paraffin embedded tissues using the DNeasy Blood and Tissue Kit (QIAGEN).

Real time PCR was done on Light Cycler Instrument (Roche Diagnostics, Mannheim, Germany) using the Light Cycler fast Start DNA Master plus SYBER Green I.

We used these primers for EBV: forward 5′CCGAAATCTGACACTTTAGAGC 3′ and reverse 5′ CCCTGACCTTTGGTGAAGTG 3′ and for HPV16: forward 5′ GGTCGGTGGACCGGTCGATG 3′ and reverse 5′ GCAATGTAGGTGTATCTCCA 3′.

The PCR protocol on Light Cycler for CYBR Green I is shown in table 1.

SYBR Green I dye binds to the minor groove of dsDNA and thus, fluorescence is enhanced. During various stages of PCR, different intensities of fluorescent signals can be detected depending on the amount of dsDNA that is present. All DNA become single stranded after denaturation. At this stage of reaction, SYBR Green I dye will not bind and the intensity of fluorescent signal is low.

During annealing, the PCR primers hybridize to the target sequence resulting in small parts of dsDNA to which SYBR Green I dye can bind and therefore increasing fluorescent signal intensity. In the elongation phase, the PCR primers are extended and more SYBR Green I dye can bind. At the end of the elongation phase, all DNA has become double stranded and a maximum amount of dye is bound. The fluorescence is recorded at the end of the elongation phase and increasing amount of PCR product can be monitored from cycle to cycle.

Interpretation of results:

Fluorescence measurement at the end of the elongation step of every PCR cycle was performed to monitor the increasing amount of amplified DNA (in positive cases) and no fluorescence signals in the negative cases (figure 1 and figure 2). In each run, one negative control was used. The DNA extraction and real time PCR (RT-PCR) were done at PCR laboratory, South Egypt Cancer Institute, Assiut University.

Statistics

All statistical analyses were performed using SPSS 16. The comparison levels and parameters were analyzed by a non-parametric test (Mann–Whitney),to evaluate the significant difference between them. A *p*-value of <0.05 was considered to be statistically significant.

Results:

Distribution of SCC and AB according to demographic characteristics is shown in Table 2.

HPV results*:* HPV was detected among 2/15 (13.3%) of SCC cases. Of these two cases, one was moderately differentiated while the other was poorly differentiated. The positivity of HPV in the moderately differentiated case was lower than that in the poorly differentiated one. This difference was proven to be statistically non-significant (P= 0.4). HPV was detected among 4/15 (26.6%) AB of cases. Of these cases, two of them were malignant while the other two were benign. Also, the positivity of HPV was higher in malignant AB than in benign cases and the difference was proven to be statistically non-significant (P= 0.5) (Table 3 and Table 4).

EBV results: EBV was detected among 3/15 (20%) of SCC cases. Of these three cases, one was well differentiated, one was moderately differentiated and the third was poorly differentiated. The positivity of EBV in the well differentiated case was higher than that in the moderately differentiated case but lower than that in the poorly differentiated case. This difference was proved to be statistically non-significant (p=0.7). EBV was detected among 4/15 (26.6%) of AB cases. The four cases of AB were benign. The positivity of EBV was zero in malignant AB and 36.4% of benign AB. This difference was also proven to be statistically non-significant (p=0.4). (Table 3 and Table 4)

Correlation between positivity of HPV and severity of SCC: A strong positive correlation existed between the positivity of HPV and severity of SCC (r=0.34) which was found to be statistically non-significant (p=0.2). (Figure 3)

Correlation between positivity of EBV and severity of SCC: A fair positive direct correlation existed between the positivity of EBV and severity of SCC (r=0.08) which was found to be statistically non-significant (p=0.7) (Figure 4)

Correlation between positivity of HBV and severity of AB: A strong positive direct correlation existed between the positivity of HBV and severity of AB (r=0.31) which was found to be statistically non-significant (p=0.1). (Figure 5)

Correlation between positivity of EBV and severity of AB: A strong negative inverse correlation existed between the positivity of EBV and severity of AB (r=0.36) which was found to be statistically non-significant (p=0.1). (Figure 6)

The relation between HPV and EBV in SCC and AB:

In SCC: among EBV positive cases 66.7% were also HPV positive, while all EBV negative cases were also HPV negative and this was found to be statistically significant (p=0.002).

In AB: among EBV positive cases 50% were also HPV positive, while 81.8% of EBV negative cases were also HPV negative but this was found to be statistically non-significant (p=0.2).

Discussion:

In the present study, PCR results revealed HPV positive in 13.3% of SCC cases. These results were found to be in accordance with that reported by Halimi and Morshedi [11] who found that 20% of their OSCC specimens were HPV positive. The rate of HPV infection in patients with OSCC is 1.4% in Africa [12], 29%-67% in the United States [13], 22-90% in Taiwan [14], 33.6% in india [15] 75% in Brazil [16] and 74% in china [17]. In two meta-analysis by Miller and Johnstone [18] and Kreimer et al [19] the rates ranged between 12.9 and 55% in different areas. The rate of HPV infection in OSCC specimens in our study also falls in these ranges. The epidemiological association of HPV with OSCC was well established [20]. The prevalence of oral carcinomas reported to be associated with HPV has varied widely. This is due to differences in both the population studied and the sensitivity of the assay used for HPV detection [21]. Our results in the present study were in agreement with Gadelkarim and Merghany [22] who found a strong association between high risk HPV types 16, 18 and risk of oral cancers using PCR for detection of HPV types 16 and 18 DNA.

But this was in contrary to Ibrahim et al [23] who found that all oral carcinomas were negative for HPV with PCR. Also Elena and Fabio [24] found complete absence of HPV DNA in OSCC using PCR. kumar et al [25] performed comparative study between the Hybrid Capture II (HC-II) test and PCR based assay for detection of HPV DNA in OSCC and found that HPV DNA positivity were 32.4% using PCR and 31.5% using HC-II test. Kujan et al [26] from United Kingdom reported that all OSCC samples were negative for HPV using HC-II technique while Vidal et al [27] from Brazil studied the role of HPV using this assay in OSCC and reported 22.5% positivity of HPV DNA. They also suggested that the detection of HPV by this technique not only helped to identify viral infections, but also correspond to find out the koilocytosis on exfoliative cytology and concluded that presence of HPV might also contributed to the development of cancer, but there are many other factors such as tobacco smoking, tobacco chewing and radiation that were consistently present in persons suffering from oral malignancies.The significane of HPV DNA presence in the progression to malignancy is still unclear. It *is* clear, however, that oral carcinoma is different from cervical cancer, where HPV infection is necessary for disease development [28].

In the present study, PCR results revealed EBV positivity in 20% of squamous cell carcinoma cases. These results were found to be lower than that reported by Ching et al [29] who used microarray analysis for detection of EBVinfection in oral cancer and said that a high EBV prevalent rate of 82.5% was detected, which was greater than in all previous investigations on OSCC reported worldwide. Failure to detect EBV DNA in some studies has been described by the "*hit and run*" theory, according to which viral DNA is required only for malignancy induction, and it disappeared during uncontrolled cell cycles of the host[30] In some studies, the viral DNA has been isolated from patients with OSCC via PCR; however, the expression of viral proteins could not be determined.[31] Various descriptions have been proposed in this regard, for example, the identified viral genomes in carcinoma cells may remain un-translated, or they may originate from oropharynx and be present in the saliva and hence contaminate tumor samples without being a carcinogen.[30] It has been also proposed that the viral DNA may reside in infiltrating lymphocytes.[32] Thus, the role of EBV as a risk factor still remains controversial.

Our study detected HPV DNA in 26.6% of AB cases which were in agreement with Namin et al [33] and Sand et al [34] who reported HPV positivity by PCR in intraosseous AB and concluded that in spite of the higher percentage of HPV positivity by PCR, the explanation of entrance of the virus deeply into these intraosseous tissues remains unexplained. A study of Jang et al [35] was the first to identify positive immunohistochemical expression of HPV antibody in 30% of AB cases. Ayoub et al [36] also revealed in their immunohistochemical results a positive expression of HPV antibody in 40% of AB cases. In contrary to our study, Migaldi et al studied the real integration of HPV-DNA into AB cells by in situ hybridization and reported no evidence of presence of capsid proteins or HPV-DNA in AB tumor cells. They ruled out HPV as an etiologic factor of AB [37].

In the present study EBV DNA was detected in 26.6% of AB cases, which was in accordance with Jang et al [35] who found a PCR positivity of EBV DNA in 8 (48%) out of 17 AB cases. While Ayoub et al [36] said that immunohistochemical results revealed EBV-immunopositivity in only one case of AB. This rarity of expression of EBV immunohistochemically might be due to the fact that a more sensitive PCR assay might be useful in detecting false negative results that might appear immunohistochemically.

Statistical analysis of the present study revealed that HPV positivity was zero in well differentiated SCC, while the positivity increased from moderately differentiated to poorly differentiated SCC but this difference was proven to be statistically non-significant (p=0.4). These results were in contrary to Halimi and Morshedi [11] who found that all HPV positive cses were well differentiated, and also with Gadelkarim and Merghany [22] who found that all poorly differentiated cases were HPV negative. In the majority of the studies, OSCC related to HPV infection shows a better outcome and a reduced risk of relapse and second tumors compared with HPV negative tumors [38].

The concept of better treatment results in HPV-positive tumors has been confirmed both in patients submitted to organ preservation treatment as well as in those submitted to surgery [39]. The reason for the improved survival is unclear. However, better outcomes seem to be attributed to the ability of HPV-positive cancer cells to induce apoptotic cell death in response to DNA damage [40]. Another reason appears to be

attributed to the absence of carcinogen induced early genetic changes in the epithelium and the development of multifocal tumors ("field cancerization concept") [41]. A better understanding of HPV-associated carcinogenesis is necessary for the development of HPV-targeted strategies. In the absence of cell mutations -classically associated with carcinogenesis in tobacco associated oropharyngeal cancers- the repression of E6 and E7 expression in HPV-positive carcinomas results in restoration of Rb and p53 tumor suppressor pathways and is sufficient to arrest cell growth or cause apoptosis.

In fact, HPV associated cancers constantly express the HPV E6 and E7 viral oncogenes even in the late stages of the disease, and repression of viral oncogene expression by drugs that interfere with the expression or function of viral proteins can induce senescence or apoptosis of cancer cells. Moreover, therapeutic vaccines that elicit a cytolytic immune response to cells expressing viral proteins could be curative possibly even in the advanced stages of the disease [42].

Statistical analysis of the present study revealed that a strong positive correlation existed between the positivity of HPV and severity of SCC (r=0.34) which was found to be statistically not significant (P=0.2). This finding might lead to the argument that when the positivity of HPV increased, the severity of SCC increased, this result consistent with the result of Szarka et al who concluded that HPVs may be involved in the development or progression of not only OSCC but also of potentially malignant oral lesions [43]. .

Our results might be explained by the fact that HPV related oropharyngeal carcinomas are not only distinct clinically, but also microscopically and molecularly. The tumors are characterized by non-keratinizing basaloid cell morphology. Microscopically, the neoplastic cells are generally monomorphic, oval or spindle shaped, with hyperchromatic basophilic nuclei, inconspicuous cytoplasm and indistinct cell borders. Palisading of the peripheral cells may be present. Excessive mitosis and apoptosis are observed. Keratinization and keratin pearl formation are generally absent although some trend towards cell maturation may occasionally be present in focal areas [44].

Our study also revealed that the positivity of EBV was higher in well-differentiatedSCC than in moderately differentiated cases but lower than the positivity in poorly differentiated cases. This difference was proven to be statistically non-significant (P=0.7). These results were in agreement with the results of Soo and Ho [45], who said that EBV – positive gastric carcinomas were mostly of the poorly differentiated type.

This study also revealed that a fair positive correlation existed between the positivity of EBV and severity of SCC (r=0.34) which was found to be statistically non-significant (P=0.2). In contrast to our results, there was no significant correlation between EBV infection and histological differentiation of the carcinoma [46] while EBV- positive gastric carcinomas showed favourable outcome when metastatic carcinomas were evaluated [47].

PCR results of the present study revealed that the positivity of HPV was higher in malignant AB than in benign AB, but this difference was proven to be statistically non-significant (P=0.5). These results were in accordance with Sand et al [34] and Ayoub et al [36].These results might be explained by the finding that HPV-DNA was detected by PCR in recurrent cases of AB only at secondary surgery indicating that this positive reaction might be due to surgical manipulation causing tumor contamination from the adjacent surface mucosal epithelium. Statistical analysis also revealed that a strong positive direct correlation existed between the positivity of HPV and severity of AB (r=0.31) which was found to be statistically non-significant (P=0.1). Positivity for HPV-DNA (types 16 and 18) was demonstrated by in situ hybridization in an extraosseous peripheral AB arisen in a 16 year-old black male suggesting that HPV might have a role, if not directly involoved, in promoting tumor cell growth. The positive nuclear reaction was evidenced in peripheral columnar epithelial cells and in a few central stellate reticulum cells [48]. Type 18 HPV was detected in a case of intraosseousAB by Van Heerden et al [49] using radiolabelled in situ hybridization. Since the viral DNA was observed only in a veracious lesion located in adjacent cystic area but not in the tumor epithelia component, this finding was considered to represent a secondary viral infection.

HPV positivity employing a PCR analysis was reported in 20 out of 50 samples of AB and in 9 out of 50 impacted third molar follicles used as normal control group by Namin et al [33]. Given that none of the above works demonstrated a real integration of HPV-DNA into the tumor cells of AB, the majority of these authors correctly underlined that the presence of HPV-DNA positivity in AB likely represented a secondary surgically acquired contamination from the overlying oral mucosa or a secondary event rather than a true infection [49]. AB generally arises from the epithelial lining of dentigerous cysts, enamel organ or from the basal layer of the oral mucosa and it is therefore, sequestered within the bone and relatively unexposed to HPV. Thus, it is more likely that the viral presence merely represented a biologic bystander without changes related to active infection [50].

PCR results also revealed that EBV-DNA was detected only in benign AB cases (36.4%), while all malignant cases were EBV negative. These results were linear with Ayoub et al [36] who said that EBV immunopositivity was found only in one case of AB while all malignant cases were immunonegative.

Statistical analysis also revealed a strong negative inverse correlation was present between the positivity of EBV and the severity of AB (r=0.36) which was found to be statistically non-significant (P=0.1). This was in contrary to what reported by Jang et al [35] who found a PCR positivity of EBV-DNA in 8 (48%) of 17 cases of AB. This contradiction might be due to the fact that a more sensitive PCR assay might be useful in detecting false negative results that might appear by immunohistochemistry, a notice that has to be taken into consideration when studying the role of EBV in development of AB and malignant AB. They also concluded that of EBV regions used for PCR, the *BamC* gene was detected in odontogenictumors.

Statistical analysis regarding the relation between EBV and HPV among patients with SCC revealed that among EBV positive cases, 66.7% were also HPV positive while all EBV negative cases were also HPV negative. This was found to be statistically significant (P=0.002). This finding might lead to the argument that HPV and EBV might be considered as causative factors for SCC On the contrary, statistical analysis regarding the relation between HPV and EBV among patients with AB revealed that 50% of EBV positive cases were also HPV positive while 81.8% of EBV negative cases were HPV negative but this was found to be statistically non-significant (P=0.2). This finding might lead to the argument that HPV and EBV are not strongly associated with the etiology of AB.

Conclusion:

Our results suggest the following:

- The current study provides support regarding the contributing role of HPV and EBV infections in the aetiology of OSCC.
- Presence of HPV-DNA could be used as an indicator for aggressiveness of SCCs as strong correlation was found between the positivity of HPV and the severity of SCC.

- Presence of EBV-DNA is not a reliable indicator for aggressiveness of SCC as a fair correlation was found between positivity of EBV and the severity of SCC.
- HPV might be implicated in the etiology of AB and hence in malignant transformation of this tumor as a strong positive correlation was found between the positivity of HPV and the severity of AB.
- **Conflict of interest disclosure**
- The author has no financial conflicts of interest to disclose.

Refferences

1. Argiris A, Karamouzis MV, Raben D et al (2008) Head and neck cancer.Lancet371:1695–1709.

2. Ferlay J, Shin HR, Bray F et al (2010) Cancer Incidence and Mortality Worldwide: IARC Cancer Base International Agency for Research on Cancer.Available from: http://globocan.iarc.fr, accessed on 30/05/2013.

3. Luo HY, and Li TJ (2009) Odontogenictumors: A study of 1309 cases in a Chinese population. Oral Oncol 45:706–711.
4. Mendenhall WM, Werning JW, Fernandes R et al (2007) Ameloblastoma. ClinOncol 30:645–648.
5. Parkin, D M (2006) The global health burden of infectionassociated cancers in the year 2002. Int. Cancer 118: 3030–3044.
6. Bouvard, V (2009) A review of human carcinogens-part B:biological agents.Lancet Oncol 10:321–322.
7. Goldie, S J (2004) Projected clinical benefits and cost effectiveness of a human papillomavirus 16/18 vaccine. Natl Cancer Inst96: 604–615.
8. Lavanchy, D (2004) Hepatitis B virus epidemiology, disease burden, treatment, and current and emerging prevention and control measures. Viral Hepat 11: 97–107.
9. ZurHausenH (2009) Papillomaviruses in the causation of human cancers - a brief historical account. Virology 384:260-265.

10. Wang C C, Chen M L, Hsu K H (2000) Second malignant tumors in patients with nasopharyngeal carcinoma and their association with Epstein-Barr virus. international Journal of Cancer 87:228–231.
11. Halimi M and Morshedi S (2011). Human papilloma virus infection in lung vs. Oral squamous cell carcinoma: A polymerase chain reaction study. Biological sciences 14:641-646.
12. Van Rensburg, E J S, Engelbrecht, W F P, Van Heerden E J et al (1996) Human Papillomavirus DNA in oral squamous cell carcinoma from African population sample.Anticancer Res 16: 969-973.
13. Summersgill K F, Smith E M, kirchner H L et al (2000) P53 Polymorphism, human papillomavirus infection in oral cavity . oral cancer oral surg oral med oral pathol90: 334-339.
14. Luo CW, Roan C H, Liu C J (2007) Human papillomaviruses in oral squamous cell carcinoma and pre –cancerous lesions detected by PCR based gene chib array. Int. j .Oral. Maxillofas.Surg36: 153-158.
15. Nagpal J K, Patnaik S, Das B R (2002) Prevalence of high risk human papillomavirus types and its association with P53 codon 72 polymorphism in tobacco addicted oral squamous cell carcinoma patients of Eastern India. Int. J. Cancer97: 649-653.
16. Xavier S D, Filho I B, LancellottiCL (2005) Prevalence of histological findings of human papillomavirus in oral and oropharyngeal squamous cell carcinoma biopsies: Preliminary study Braz. J. Otorhinolartngol 71: 510-514.
17. Zhang Z Y, Sdek P, Cao J et al (2004) Human papilloma virus type 16 and 18 DNA in oral squamous cell carcinoma and normal mucosa. Int. J. Oral. Maxillofac. Surg33: 71-74.
18. Miller C S and Johnstone B M (2001) Human papillomavirus as a risk factor for oral squamous cell carcinoma: A meta-analysis, 1982-1997.Oral Surg. Oral Med. Oral Pathol. Oral Radiol. Enddod 91: 622-635.
19. Kreimer A R, Clifford G M, Boyle p et al (2005) Human papillomavirus types in head and neck squamous cell carcinomas worldeide: A systematic review. Cancer Epidemiol. Biomarkers rev 14: 467-475.
20. Oliveira MC, Soares RC, Pinto LP et al (2009) High-risk human papillomavirus (HPV) is not associated with p53 and bcl-2 expression in oral squamous cell carcinomas. AurisNasus Larynx 36: 450-456.

21. Lee SY, Cho NH, Choi EC (2010) Relevance of human papillomavirus (HPV) infection to carcinogenesis of oral tongue cancer.Int J Oral MaxillofacSurg 39: 678-683.105

22. Gadelkarim H A, and Merghany F E (2010) Detection of Human Papilloma Virus Types 16 and 18 among Sudanese Patients with Oral Squamous Cell Carcinoma. The Open Cancer Journal 3:130-134.

23. Ibrahim SO, Bertelsen B, KalvenesMB (1998) Expression of keratin 13, 14 and 19 in oral squamous cell carcinomas from Sudanese snuff dippers: lack of association with human papillomavirus infection. APMIS 106: 959-969.

24. Elena R C and Fabio D (2006) HPV In oral squamous cell carcinomas of a Brazilian population: amplification by PCR. Brazoralres 20: 21

25. Kumar A , Pandya S, Mehrotra R, et al (2010) Comparative study between the Hybrid Capture II test and PCR based assay for the detection of human papillomavirus DNA in oral submucous fibrosis and oral squamous cell carcinoma. Virol 7: 253.

26. Kujan O, Desai M, Sargent A et al (2006) Potential applications of oral brush cytology with liquid-based technology: results from a cohort of normal oral mucosa. Oral Oncol 42:810–818.

27. Vidal A, Junior A, Mello R (2004) HPV detedtion in oral carcinoma. J Bras Patol Med Lab 40:21–26.

28. Patrick k. Ha and joseph a. Califano: the role of human papillomavirus In oral carcinogenesis. *Crit rev oral biol med 2004 :15(4):188-196*

29. Ching Yu Ye, Min C L, Ching C T et al (2009) Detection of EBV Infection and Gene Expression in Oral Cancer from Patients in Taiwan by Microarray Analysis . Biomed Biotechnol 2009: 904589.

30. Hermann RM, Füzesi L, Pradier O, Christiansen H, Schmidberger H. Presence of human papillomavirus-18 and *Epstein-Barr* virus in a squamous cell carcinoma of the tongue in a 20-year-old patient. Case report and review of the current literature. Cancer Radiother. 2004;8:262–5.

31. 31. Kis A, Fehér E, Gáll T, Tar I, Boda R, Tóth ED, et al. *Epstein-Barr* virus prevalence in oral squamous cell cancer and in potentially malignant oral disorders in an eastern Hungarian population. Eur J Oral Sci. 2009;117:536–40.

32. 32. Cruz I, Van Den Brule AJ, Brink AA, Snijders PJ, Walboomers JM, Van Der Waal I, et al. No direct role for Epstein-Barr virus in oral carcinogenesis: A study at the DNA, RNA and protein levels. Int J Cancer. 2000;86:356–61.

33. Namin AK, Azad TM, EslamiB (2003) A study of the relationship between ameloblastoma and human papilloma virus. Oral MaxillofacSurg61: 467–470.
34. Sand L, Jalouli J, Larsson PA (2000) Presence of human papilloma viruses in intraosseousameloblastoma. Oral MaxillofacSurg58: 1129–1134.
35. Jang HS, Cho JO, Yoon CY et al (2001) Demonstration of Epstein-Barr virus in odontogenic and nonodontogenictumors by the polymerase chain reaction (PCR). J Oral PatholMed 30: 603-610.
36. Ayoub MS, Elmalahy MH, ElshafeiMM (2011) Expression of Human Papilloma Virus and Epstein BarrVirus in Benign and Malignant Ameloblastoma. International Journal of Academic Research 3(2).
37. Migaldi M, Pecorari M, Rossi G et al (2005) Does HPV play a role in the etiopathogenesis of ameloblastoma? An immunohistochemical, in situ hybridization and polymerase chain reaction study of 18 cases using laser capture microdissection.Modern Pathology 18: 283–289.
38. D'Souza G. (2007) Case-control study of human papillomavirus and oropharyngeal cancer. N Engl J Med 356:1944-1956.
39. Worden FP, Kumar B, Lee JS et al (2008) Chemoselection as a strategy for organ preservation in advanced oropharynx cancer: response and survival positively associated with HPV16 copy number. J ClinOncol 26:3138-3146.
40. Butz K, Geisen C, Ullmann A et al (1999) Cellular responses of HPV-positive cancer cells to genotoxic anti-cancer agents: repression of E6/E7-oncogene expression and induction of apoptosis. Int J Cancer 68:506-513.
41. Slaughter DP. (1953) Field cancerization in oral stratified squamous epithelium; clinical implications of multicentric origin. Cancer 6:963-968.
42. Marta Rossi, Werner Garavello, Renato Talamini(2007) Flavonoids and Oral and Pharyngeal Cancer Risk. Cancer Epidemiol Biomarkers Prev 16(8): 1621-1625.
43. Szarka K[1], Tar I, Fehér E, Gáll T, Kis A, Tóth ED, Boda R, Márton I, Gergely L. Progressive increase of human papillomavirus carriage rates in potentially malignant and malignant oral disorders with increasing malignant potential. Oral Microbiol Immunol. 2009 Aug;24(4):314-8

44. Reichart PA, and Philipsen HA. (2004) Desmoplasticameloblastoma: odontogenictumors and allied lesions. London . Quintessence Publishing Co Ltd 69–76.
45. Soo M C and Ho W (2005) Epstein-Barr Virus in Human Malignancy: A Special Reference to Epstein-Barr Virus associated Gastric Carcinoma. Cancer Res Treat 37: 257–267.
46. Higa M, Kinjo T, Kamiyama K, Iwamasa T et al (2002) Epstein-Barr virus (EBV) subtype in EBV related oral squamous cell carcinoma in Okinawa, a subtropical island in southern Japan, compared with Kitakyushu and Kumamoto in mainland Japan. J ClinPathol 55: 414–423.
47. Mastsunou H, Konishi F, Hori H et al (1996) Characteristics of Epstein-Barr virusassociated gastric carcinoma with lymphoid stroma in Japan. Cancer 77:1998–2004.
48. Perz, J F, Armstrong, G L, Farrington, L A et al (2006) 'The contributions of hepatitis B virus and hepatitis C virus infections to cirrhosis and primary liver cancer worldwide. J.Hepato45:529–538.
49. Van Heerden WF, van Rensburg EJ, RaubenheimerEJ et al (1993) Detection of human papillomavirus DNA in an ameloblastoma using the in situ hybridization technique. Oral PatholMe22: 109-112.
50. Eisenberg E (2000) Presence of human papilloma viruses in intraosseousameloblastoma.Oral MaxillofacSurg 58: 1135–1136.

Table 1: PCR protocol on Light Cycler for SYBRGeen I

Analysis mode	Cycle	Segment	Temperature	Hold time	Acquisition mode
Pre-incubation					
None	1		95 C°	10 min.	None
Amplification					
Amplification	45	Denaturation	95 C°	10 s.	None
		Annealing	C°*	10 s.	none
		Extension	72 C°	10 s.	Single
Cooling					
None	1		40 C°	30s.	None

*55C for EBV and 60 C for HPV

.

Table 2: Distribution of SCC and AB according to demographic characteristics

variable	Categories	OSCC No.	OSCC %	variable	Categories	AB No.	AB %
Age (years)	40 – 60	9	60	Age (years)	20-50	11	73.3
	60 -75	6	40		50-80	4	26.7
Sex	Male	9	60	Sex	Male	7	46.6
	Female	6	40		female	8	53.4
Site	Oral cavity proper	11	73.4	Site	Mandible	9	60
	Lip vermilion	4	26.6		Maxilla	4	26.6
					Gingiva	2	13.4
Pathology	Well differentiated	5	33.3	Pathology	Benign	11	73.3
	Moderately differentiated	7	46.7		Malignant	4	26.7
	Poorly differentiated	3	20				

Table (3): The positivity of HPV and EBV in the different grades of SCC

	HPV(+) No	HPV(+) %	HPV(-) N	HPV(-) %	P	EBV(+) No.	EBV(+) %	EBV(-) No.	EBV(-) %	P
Well differentiated (no.5)	0	0	5	100	0.007	1	20	4	80	0.005

Table (4) The positivity of EBV and HPV in Ameloblastoma

	HPV(-)		HPV(+)		P	EBV(-)		EBV(+)		P
	No.	%	No.	%		No.	%	No.	%	
Benign AB (No. 11)	2	18.2	9	81.8	0.001	4	36.4	7	63.6	0.1
Malignant AB(No. 4)	2	50	2	50	0.5	0	0	4	100	0.002

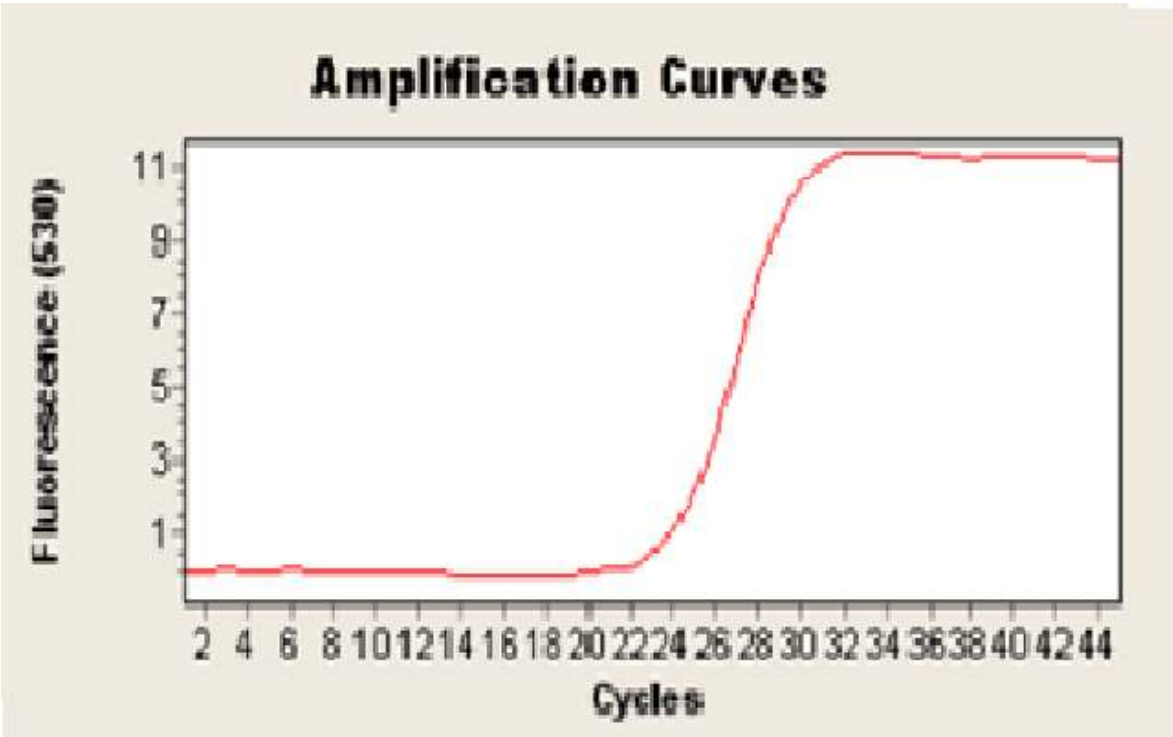

Figure 1 : Graph show positive case either EBV or HPV as shown in LightCycler screen

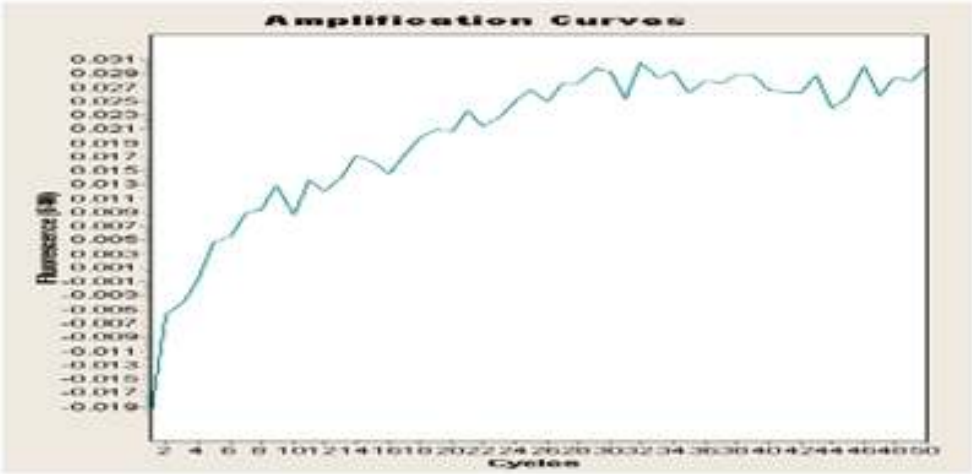

Figure 2: Negative case

Figure 2: Graph show negative case either EBV or HPV as shown in LightCycler screen

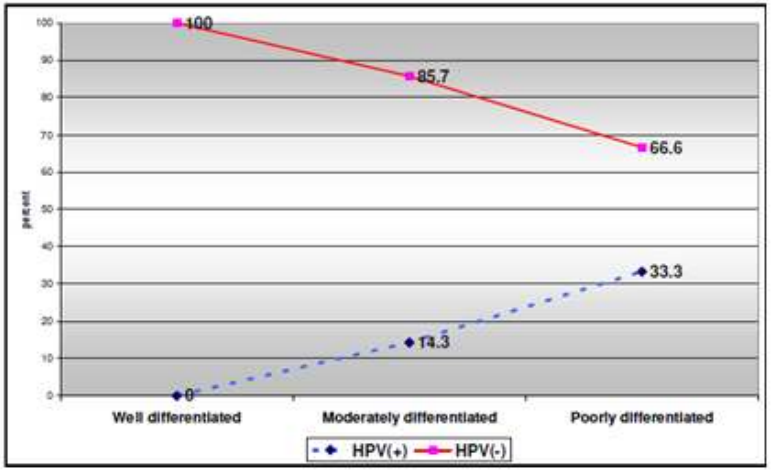

Figure 3: Line graph shows that the positivity of HPV increases between the different grades of SCC.

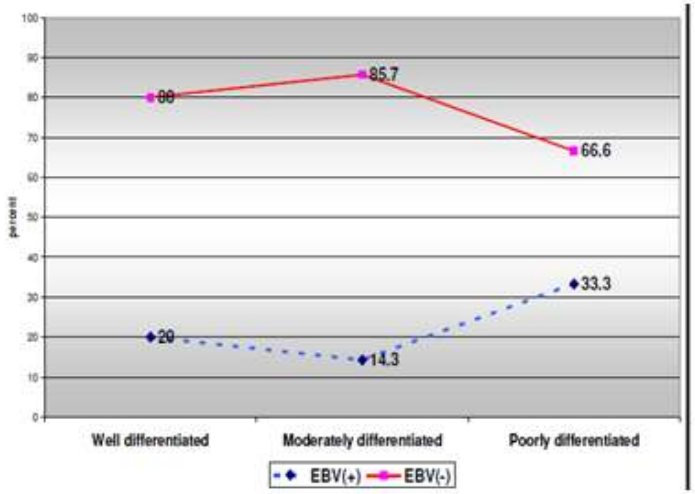

Figure 4: Line graph shows that the positivity of EBV decreases from well to moderate and increases from moderate to poorly differentiated SCC.

334

335

336

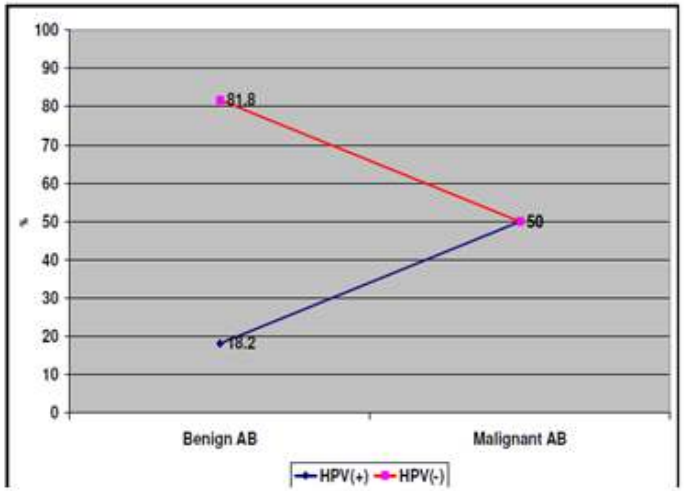

Figure 5 : Line graph shows that the positivity of HPV increases from benign to malignant AB

337

338

339

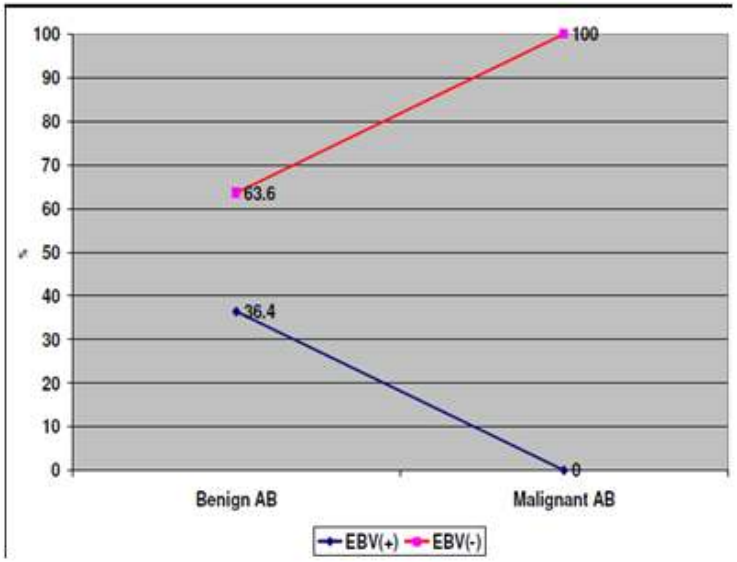

Figure 6 . Line graph shows that the positivity of EBV decreases from benign to malignant AB.

Figure 1: Graph show positive case either EBV or HPV as shown in LightCycler screen

Figure 2: Graph show negative case either EBV or HPV as shown in LightCycler screen

Figure 3: Line graph shows that the positivity of HPV increases between different gardes of OSCC

Figure 4: Line graph shows that the positivity of EBV decreases from well to moderate and increases from moderate to poorly differentiated SCC.

Figure 5: Line graph shows that the positivity of HPV increasesfrom benign to malignant AB.

Figure 6: Line graph shows that the positivity of EBV decreases from benign to malignant AB.