UNDER PEER REVIEW

Original Research Article

EVALUATION OF PHOTOCOAGULATION IN DIABETIC RETINOPATHY

Abstract

Aim

1.To study the efficacy of laser photocoagulation in Diabetic Retinopathy.

2.To study the different laser protocols used for treatment of Diabetic Retinopathy.

Materials and methods

retrospective study was conducted in the dept of ophthaImology in a tertiary eye care centre from April 2014 to July 2015.Patients presenting to the Retina Clinic with a diagnosis of Diabetic Retinopathy and undergoing laser photocoagulation were included in the study. Forty eyes of 20 patients with Diabetic Retinopathy undergoing laser were enrolled. All the patients underwent routine ophthalmological examination including FFA.

Results

Forty eyes of 20 patients with Diabetic Retinopathy undergoing laser were enrolled. There were 9 females and 11 male.Mean age was 58.4 years. 4 patients with a clinical diagnosis of Proliferative Diabetic retinopathy, 9 patients with Non Proliferative Diabetic Retinopathy, 7 patients with Non Proliferative Diabetic Retinopathy and Clinically Significant Macular Oedema. Visual acuity at presentation was more than 6/12 in 17 eyes, 6/60 to 6/18 in 21 eyes, less than 6/60 in 2 eyes.Sixteen eyes received Pan retinal Photocoagulation in 3 sittings while 16 eyes received Focal laser, 8 eyes received Grid laser, 8 eyes received Pan retinal Photocoagulation along with Focal laser, and 8 eyes received Pan retinal Photocoagulation along with Grid laser.Visual acuity after laser was during presentation was more than 6/12 in 32 eyes, 6/60 to 6/18 in 5 eyes, less than 6/60 in 3 eyes.Visual Acuity improved in 57.5% of eyes, remained same in 40% of eyes and worsened in 2.5% of eyes after laser photocoagulation.

CONCLUSION

1.Most patients with Diabetic Retinopathy presented with good visual acuity.

2. Pan Retinal Photocoagulation was effective in regressing new vessels in all eyes.

3.Focal laser was more effective than grid laser in reducing macular edema.

4.Visual acuity improved in 57.7% of eyes, remained same in 49% of the eyes and worsened in 2.5% of the eyes.

UNDER PEER REVIEW

AIM OF THE STUDY

1.To study the efficacy of laser photocoagulation in Diabetic Retinopathy.

2.To study the different laser protocols used for treatment of Diabetic Retinopathy.

Introduction

Diabetic retinopathy is the commonest cause of blindness in the population of working age in developed nations and is of increasing importance in developing nations. The prevalence of retinopathy varies with the age of onset of diabetes and the duration of the disease: in younger patients (below 30 years of age) the prevalence of retinopathy is minimal during the first 5 years but increases to greater than 95% after 15 years of diabetes. In contrast, in patients whose onset of diabetes occurs after the age of 30, up to 20% may have signs of retinopathy on presentation with the prevalence in this group rising more slowly to approach 60% after 15 years of diabetes. In an insulin-treated subset of older-onset (>30 years) diabetic patients, 30% have signs of retinopathy at diagnosis, rising to over 80% after 25 years of diabetes.[1] More recent data on patients with non-insulin dependent diabetes mellitus (NIDDM) as part of the UK Prospective Diabetes Survey (UKPDS) indicate that the prevalence of retinopathy at diagnosis is 38%, using a single micro aneurysm as evidence of retinopathy. As a general statement, therefore, the prevalence of Diabetic Retinopathy (DR)of any severity in the diabetic population as a whole is approximately 30%. [2,3]

Causes of Visual Loss In Diabetic Retinopathy[4]

The cause of visual loss in Diabetic Retinopathy is due to Proliferative Diabetic Retinopathy with Vitreous Hemorrhage and then due to Clinically Significant Macular Oedema (CSME).

Lasers in Diabetic Retinopathy

Pan Retinal Photocoagulation[5]

Laser therapy is aimed at inducing of new vessels and preventing visual loss from vitreous hemorrhage and tractional retinal detachment. The extent of treatment is dependent on the severity of Proliferative diabetic retinopathy (PDR).

Focal Photocoagulation[4,5]

UNDER PEER REVIEW

Focal photocoagulation is usually applied to focal points of leakage around 3000 µ of the fovea as revealed by fundus Fluorescein angiography or to centre of rings of hard exudates to reduce leakage.

It may also be used when there is the threat of hemorrhage into the preretinal space or vitreous body in the particular eye. In these cases focal photocoagulation directly to the neovascular areas can be considered although the chances of complications such as hemorrhage and localized retinal contraction are much greater than within direct approaches, such as pan retinal photocoagulation.

Macular Grid[5]

Grid treatment consist of burns of 50-200 µm spot size of lighter intensity than that required for pan retinal photocoagulation ,placed to one burn width apart at 0.1 second duration . The grid treatment is placed outside 500 µm from the edge of the optic disc, and not within 500µm of the center of macula.

General Therapeutic Approach**[6,7]**

The following is the sequences of procedures employed to eradicate diabetic papillary or retinal neovascularisation and the appropriate intervals between each of the individual procedures.

Stage 1: panretinal Photocoagulation	2 to 3 months
Stage 2: Additional panretinal Photocoagulation	2 to 3 months
Stage 3: Anterior Retinal Cryocautery	2 months
Stage 4: Focal Photocoagulation	2 months
Stage 5: Vitrectomy	

LASER EFFECTS ON THE EYE .

All electromagnetic radiation can reflected, transmitted, or absorbed. For the laser to be therapeutically effective within the eye it needs to be transmitted through the ocular media so that it can enter the eye and be absorbed by a chromophore.

UNDER PEER REVIEW

The possible effect of lasers on the eye depends on the site of absorption and the temperature rise at this site. The effects are photochemical, photo irradiation (raises the temperature be only a few degrees centigrade) photo coagulation (raises the temperature by 3O C and More) and photo disruption (raises the temperature up to 20 000º C)[4,5,6].

PHOTOCHEMICAL EFFECT

The effect of the light on a tissue varies according to the amount of energy absorbed. During daylight hours the retina is constantly being irradiated with visible light, yet this does not have the same effect as a laser because the energy and temporal aspects are different. In the noon day sun, the background luminance levels vary between 0.01m w\cm and 0.1mwcm of retina. At these radiances a photochemical change occurs in the retina, converting cis-retinol to trans-retinol, so initiating the perception of light.[3,4]

Although photochemical reactions can result in injury to the eye, for example, are flash photokeratitis, most light damage contains a thermal component. Irradiation even at low levels, causing only small rises in temperature, can produce damage. Fortunately most of this is transient and recovery is the rule. Photochemical damage will also occur in areas adjacent to a visible burn on the retina. The further from the burn, the greater the chance of this being reversible, but in the more adjacent areas this damage will be permanent. This is important to remember when treating in proximity to the foveola.

Whitening in the retina will occur in the retina if low dose irradiation is applied, if the laser is defocused, in the area surrounding a visible laser burn. Although there is no immediate visible damage, in time structural changes at the retinal pigment epithelium may be seen. This damage accounts for the increase in size of a laser burn which may be seen some months after the laser treatment. This enlargement of burn size as a result of photo irradiation is often greater in myopic patients who have a less pigmented retinal pigment epithelium.[3,4,5,6]

PHOTOCOAGULATION

Photocoagulation results in a visible burn in the retina, accompanied by a rise in temperature to about 30C Most of the therapeutic effects of lasers are the result of photocoagulation. To photocoagulate the retina, energy needs to be absorbed in sufficient quantities to cause a significant local temperature rise. An average luminance from a continuous wave laser, se at 1 mw, during photocoagulation is 10 000mw\cm. This is sufficient to raise the

UNDER PEER REVIEW

temperature to 30C and to coagulate the RPE. Obviously the temporal relationship is important when considering the effects of radiation on the eye, but in general damage can occur in fractions of a second with high levels of irradiance, but may not develop for some hours at lower levels of irradiance.[3,4]

PHOTO DISRUPTION

If the temperature of the target is raised to in the region of 20 000 C for a short period of time and very accurately focused, then photo disruption occurs. [8,9]The center of the reaction produces a plasma that disrupts the molecules of the tissue and the tissue evaporates this process of disruption may be produced by neodymium laser systems which are currently available in two variants: the nanosecond Nd:YAG laser and the picoseconds high frequency Nd:YLF laser which can produce 1000 pulses/second. These lasers are more commonly used in the anterior segment of the eye, but may also be used to divide or cut vitreous bands or sheets, or to open the posterior hyaloid face in cases of premacular subhyaloid hemorrhages[10,12].

Condition	Spot size(µm)	Duration millisecond	Power Milli watts	Intensity	Number	Location
CSME						
Focal	50 -100	50 - 100	50 - 100	Whiten micro aneurysms	To all leaking microaneurysms.	500µ away from fovea
Grid	50 – 200	50 – 100	50 -100	Mild light burns	Area of diffuse DME	500µ away from fovea
PDR						
Scatter	500	100	200 - 300	Moderate intensity	1200 -1600	½ burn width apart. 2DD from centre of macula and 500µ from disc
Direct	500	100	200 - 300	Moderate intensity	Overlapping confluent	2DD from centre of macula and 500µ from disc

Recommended techniques for laser treatment: Laser 532µm[9,10,11,12]

UNDER PEER REVIEW

MATERIALS AND METHODS

This retrospective study was conducted in the dept of ophthaImology in a tertiary eye care centre from April 2014 to July 2015.Patients presenting to the Retina Clinic with a diagnosis of Diabetic Retinopathy and undergoing laser photocoagulation were included in the study.

Inclusion Criteria

1. Patients receiving pan retinal photocoagulation or focal laser or grid laser for diabetic retinopathy
2. Patients with at least one month of follow up

Exclusion Criteria

1. Patients who did not completed full course of lasers.
2. Patients with less than one month of follow up.

Basic Protocol

All patients with Diabetic Retinopathy with macular oedema or new vessels underwent Fundus Fluorescein Angiography. Following this, a decision was made regarding type and number of laser sittings. Patients with Proliferative Diabetic Retinopathy received, three sittings of Pan Retinal Photocoagulation (PRP) with an aim to cover retina from posterior pole to a far as periphery as possible. Patients with associated macular oedema received focal or grid laser with the first sitting of laser .Patients with macular oedema received focal or grid laser depending on whether they had focal or diffuse macular oedema. Visual acuity was recorded with Snellen chart before and one month after the completion of laser. All lasers were given with Zeiss slit lamp delivery system. Double Frequency Nd-Yag laser is delivered using Mainster Contact Lens.

Data Collection

Data collected includes age, sex, type of Diabetic Retinopathy, presence of Macular Oedema, presenting visual acuity, number of laser sittings, type of laser protocol, number of burns, power, size, duration were recorded.

UNDER PEER REVIEW

Following this, one month after laser was completed, regression of new vessels and decrease in Macular oedema was noted and visual acuity was noted.

RESULTS

This retrospective study was conducted in the dept of ophthalmology in tertiary eye care centre from April 2014 to July 2015.

Forty eyes of 20 patients with Diabetic Retinopathy undergoing laser were enrolled. There were 9 females and 11 males. (Table-1).Mean age was 58.4 years. There were 4 patients with a clinical diagnosis of Proliferative Diabetic retinopathy, 9 patients with Non Proliferative Diabetic Retinopathy, 7 patients with Non Proliferative Diabetic Retinopathy and Clinically Significant Macular Oedema.(Table-2).

Fundus Fluorescein Angiography was performed in all patients and showed new vessels in 6 eyes, significant capillary non perfusion areas in 10 eyes, diffuse macular leaks in 4 eyes, and focal leaks at the posterior pole in 20 eyes.Visual acuity at presentation was more than 6/12 in 17 eyes, 6/60 to 6/18 in 21 eyes, less than 6/60 in 2 eyes.(Table-3).

Sixteen eyes received Pan retinal Photocoagulation in 3 sittings while 16 eyes received Focal laser, 8 eyes received Grid laser, 8 eyes received Pan retinal Photocoagulation along with Focal laser, and 8 eyes received Pan retinal Photocoagulation along with Grid laser.

Mean laser settings for Pan retinal Photocoagulation were 304mW power, 211msec duration and 256 μ spot size. About 390 spots were delivered per sitting.

Mean laser sittings for Focal grid were laser were 218 mW power, 204 msec duration and 107 μ spot size. Each eye received an average of 46 spots per sitting.

Following laser photocoagulation, new vessels is regressed in all the 6 eyes. The macular edema improved in 6 eyes and worsened in 8 eyes. Focal leaks along with hard exudates improved in 18 eyes and remained unchanged in 2 eyes.

Visual acuity after laser was during presentation was more than 6/12 in 32 eyes, 6/60 to 6/18 in 5 eyes, less than 6/60 in 3 eyes.(Table-4).

UNDER PEER REVIEW

Visual Acuity improved in 57.5% of eyes, remained same in 40% of eyes and worsened in 2.5% of eyes after laser photocoagulation.

TABLE – 1

SEX DISTRIBUTION

S.No	Sex	No. of Patients
1	Female	9
2	Male	11

TABLE – 2

TYPES OF DIABETIC RETINOPATHY

S.No	Types of Diabetic Retinopathy	No. of Patients
1	NPDR	9
2	PDR	4
3	NPDR with CSME	7

UNDER PEER REVIEW

VISUAL ACUITY BEFORE LASER TREATMENT

TABLE – 3

Visual Acuity	No. Of patients
6/6-6/12	17
6/18-6/60	21
>6\60	2

TABLE – 4

VISUAL ACUITY AFTER LASER TREATMENT

Visual Acuity	No. Of patients
6/6-6/12	32
6/18-6/60	5
>6/60	3

UNDER PEER REVIEW

PICTURE – 1

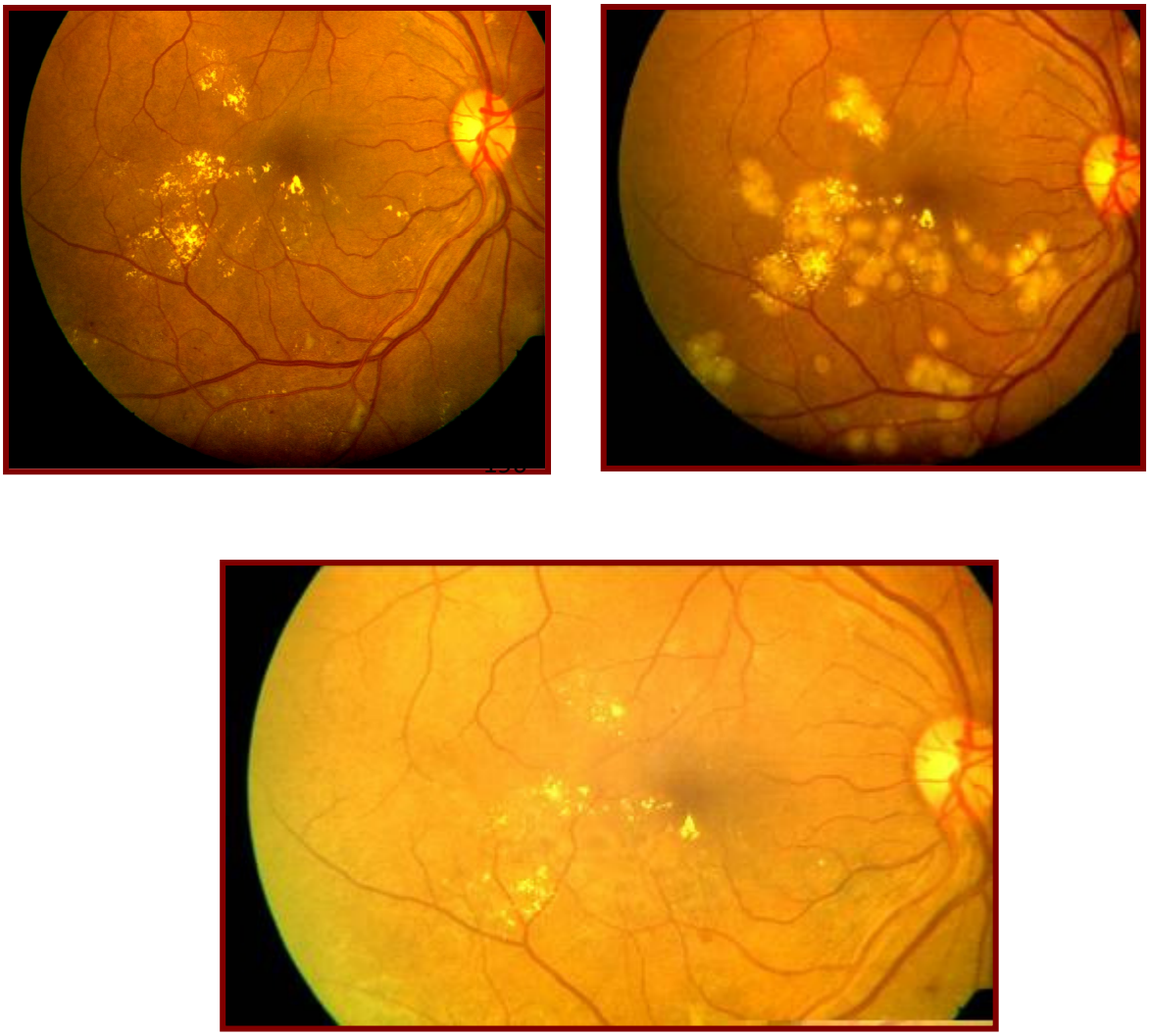

Severe non proliferative diabetic retinopathy with clinically significant macular oedema before laser (top left), immediately after laser (top right) and 1 month after laser (bottom). hard exudates and macular oedema have resolved

PICTURE - 2

UNDER PEER REVIEW

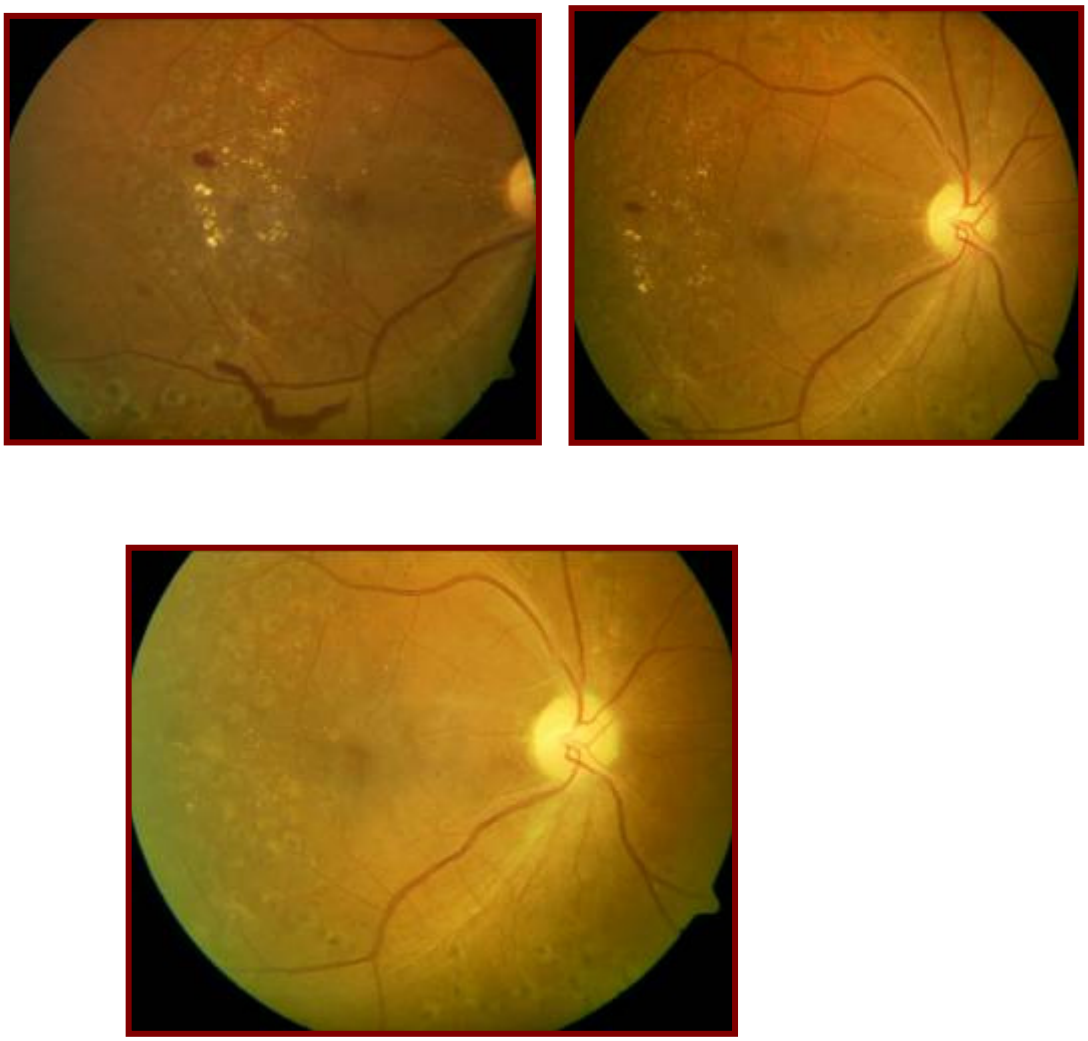

Proliferative diabetic retinopathy after grid laser and PRP. macular oedema and pre-retinal haemorrhage have resolved

PICTURE - 3

UNDER PEER REVIEW

Severe proliferative diabetic retinopathy with NVD

PICTURE - 4

Proliferative diabetic retinopathy with NVD and fibrous tissue

UNDER PEER REVIEW

PICTURE - 5

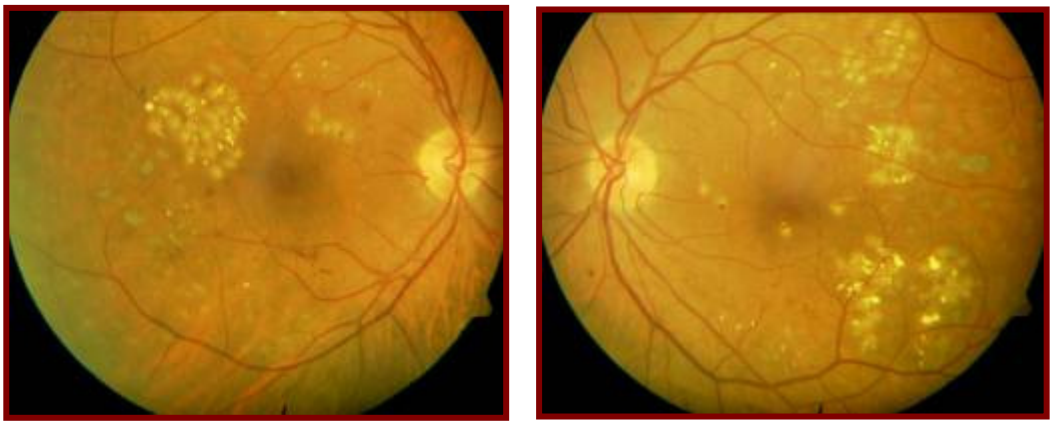

UNDER PEER REVIEW

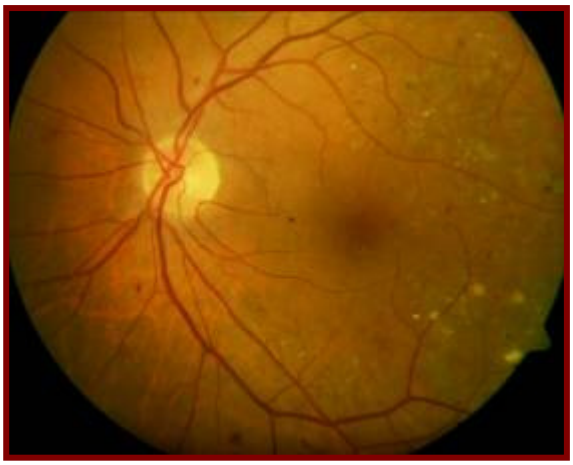

Non proliferative diabetic retinopathy with CSME immediately after focal laser (top) and 1 month after focal laser (bottom). oedema and hard exudates have resolved

PICTURE - 6

Pan retinal photocoagulation for proliferative diabetic retinopathy

UNDER PEER REVIEW

DISCUSSION

This was a retrospective analysis of clinical data that was conducted at Dept of ophthalmology in tertiary eye care centre to study the role and effectiveness of laser photocoagulation in the treatment of diabetic retinopathy.

In this study, data of 40 eyes of 20 patients with diabetic retinopathy were analysed. These patients underwent Fundus Fluorescein Angiography (FFA) followed by laser photocoagulation. There were 14 eyes with NPDR with CSME, 8 eyes with PDR and 18 eyes with NPDR.

Of the 8 eyes with PDR, all eyes had appreciable regression of new vessels following three sittings of Pan Retinal Photocoagulation. This compares with the results of the diabetic retinopathy study which proved the efficacy of Pan Retinal Photocoagulation in the treatment of Proliferative diabetic retinopathy. In 2 eyes injection bevacizumab intravitreally was regressed as new vessels failed to completely resolve with Pan Retinal Photocoagulation (PRP).

Of the 14 eyes with CSME, 8 eyes had focal laser and 6 eyes had grid laser. Visual acuity improved after laser in 10 eyes, remained same in 2 eyes and worsened after laser in 2 eyes. This compares favourably with ETDRS study which showed the efficacy of focal or grid laser in preventing visual loss due to CSME. In the 3 eyes where macular Oedema failed to improve after laser, intravitreal triamcinolone acetonide (IVTA) was injected.

CONCLUSION

1.Most patients with Diabetic Retinopathy presented with good visual acuity.

2. Pan Retinal Photocoagulation was effective in regressing new vessels in all eyes.

3.Focal laser was more effective than grid laser in reducing macular edema.

4.Visual acuity improved in 57.7% of eyes, remained same in 49% of the eyes and worsened in 2.5% of the eyes.

References

1. Meyer – Schwickerath GRE, Schott K: Diabetic Retinopathy and Photocoagulation. *American Journal Ophthalmology* 66:597-603, 1968 .
2. Venkatesh Pradeep: Lasers in Ophthalmology .2002.
3. AMP Hamilton, M Wulbig and P. Polkenghorhe: Management of Diabetic Retinopathy .First Edition .2003
4. Ramanjith Sihota and Radhika Tandon: Parson's Diseases of The Eye .Twentieth Edition 2007.

UNDER PEER REVIEW

5. Wayne. F. March. MD : Ophthalmic Lasers . 1990
6. Jack J Kanski : Clinical Ophthalmology – A Clinical Approach . Fifth Edition.2003.
7. Francis A. L'Espearance 'Jr: Ophthalmic Lasers, Photocoagulation, Photo radiation, and Surgery . 1975
8. Early treatment Diabetic Retinopathy Study Research Group. Photocoagulation for diabetic macular oedema. Early treatment diabetic retinopathy study report number *Archives of Ophthalmology* 1985 103:1796-806.
9. Early treatment Diabetic Retinopathy Study Research Group. Photocoagulation for diabetic macular oedema. Early treatment diabetic retinopathy study report number *Archives of Ophthalmology* 1985 103:1796-806.
10. The Diabetic Retinopathy Study Research Group. Preliminary report on effects of Photocoagulation therapy. *American Journal of Ophthalmology* 1976; 108: 81-96.
11. The Diabetic Retinopathy Study Research Group. Preliminary report on effects of Photocoagulation therapy. *American Journal of Ophthalmology* 1976; 108:81-96.
12. Rajavardhan Azad and Hem .K .Tewari : Current Concepts in ophthalmic Lasers.1992